

# Surgical Overview

Andrea Bischoff, MD

---

Peña Course for Nurses and Advanced Practice Providers

April 8<sup>th</sup>, 2021



Children's Hospital Colorado

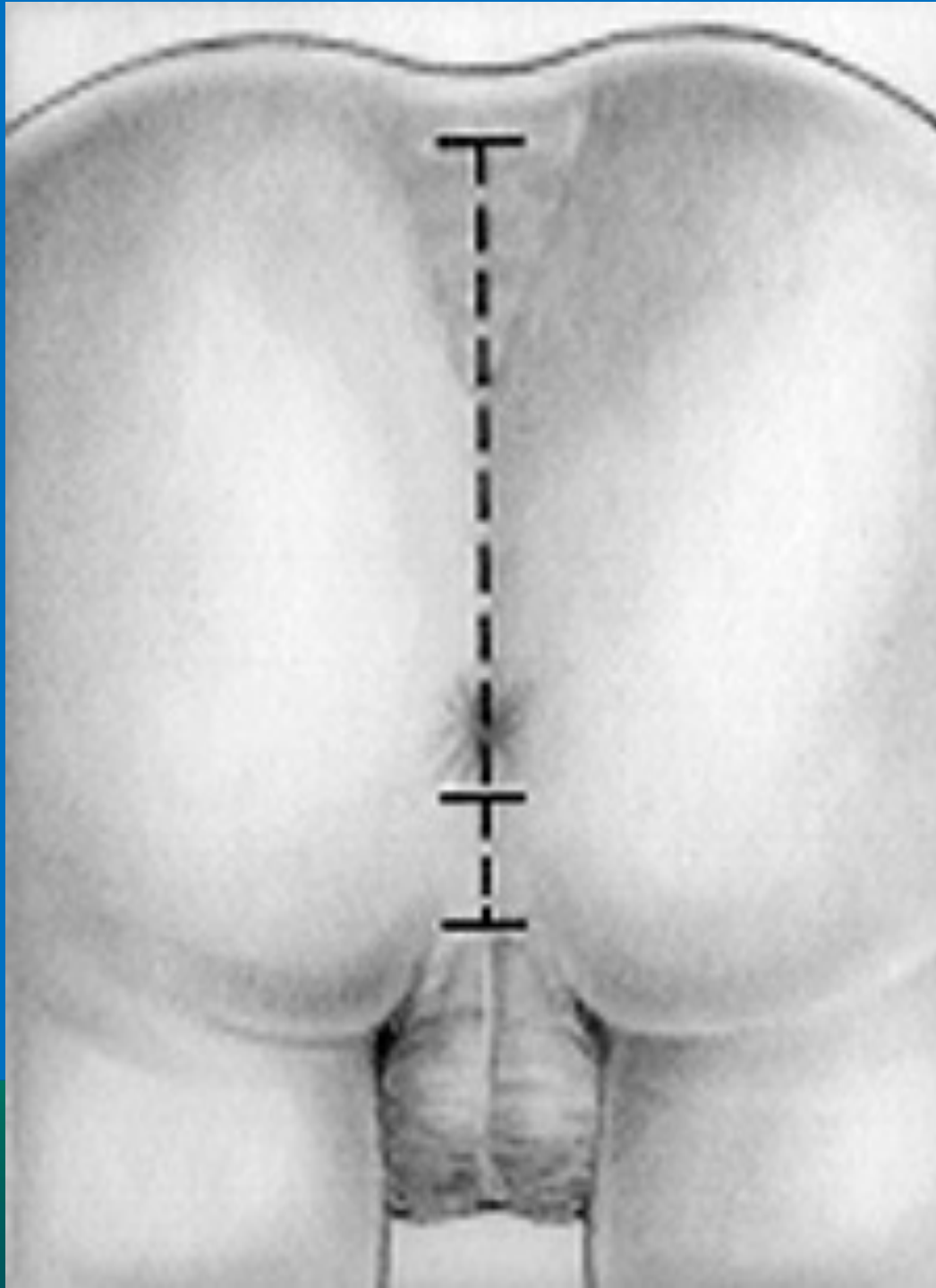
INTERNATIONAL CENTER FOR  
**COLORECTAL AND  
UROGENITAL CARE**

# August 10<sup>th</sup>, 1980

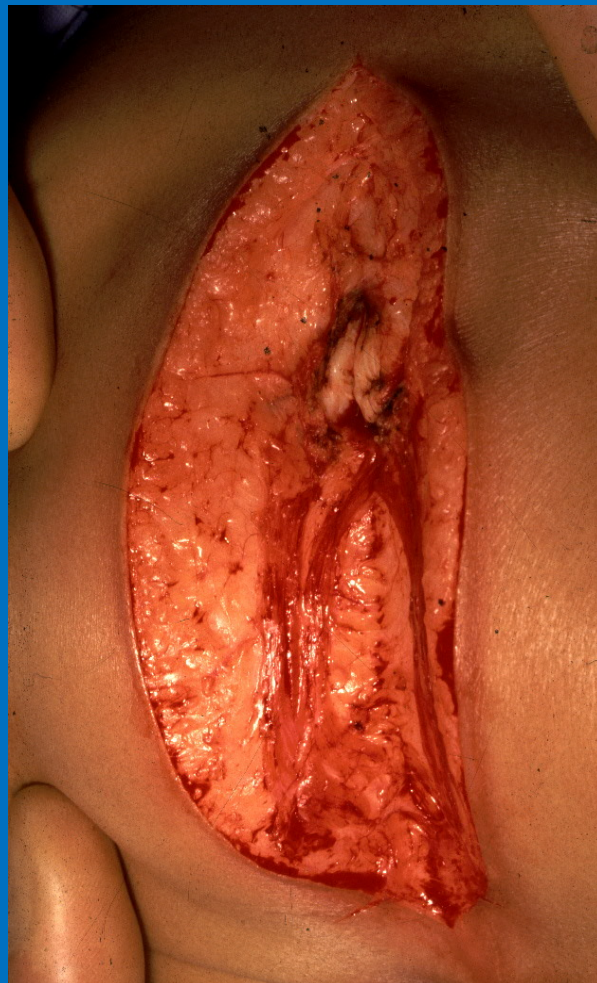
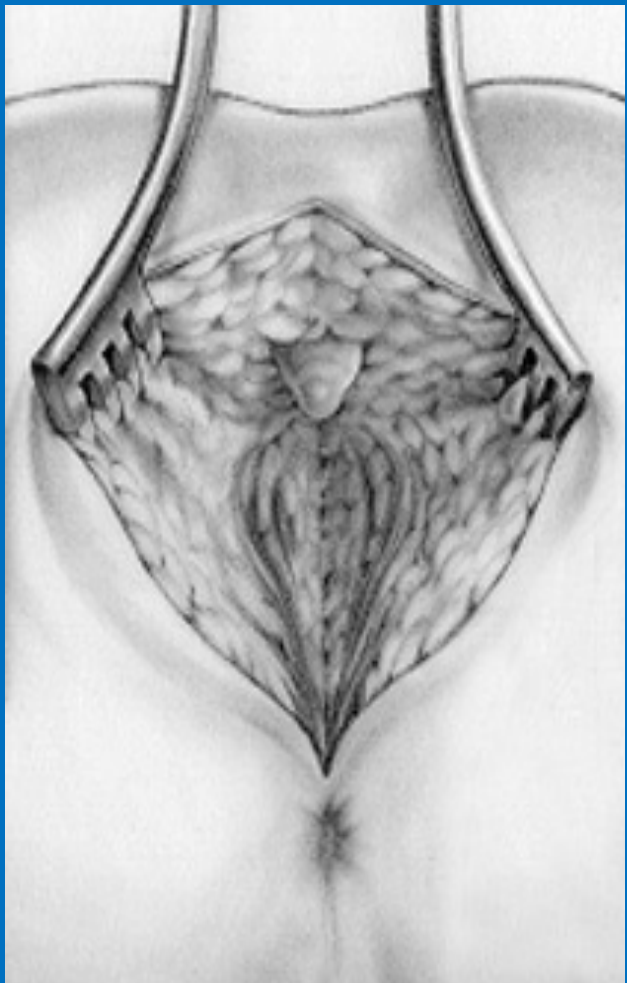


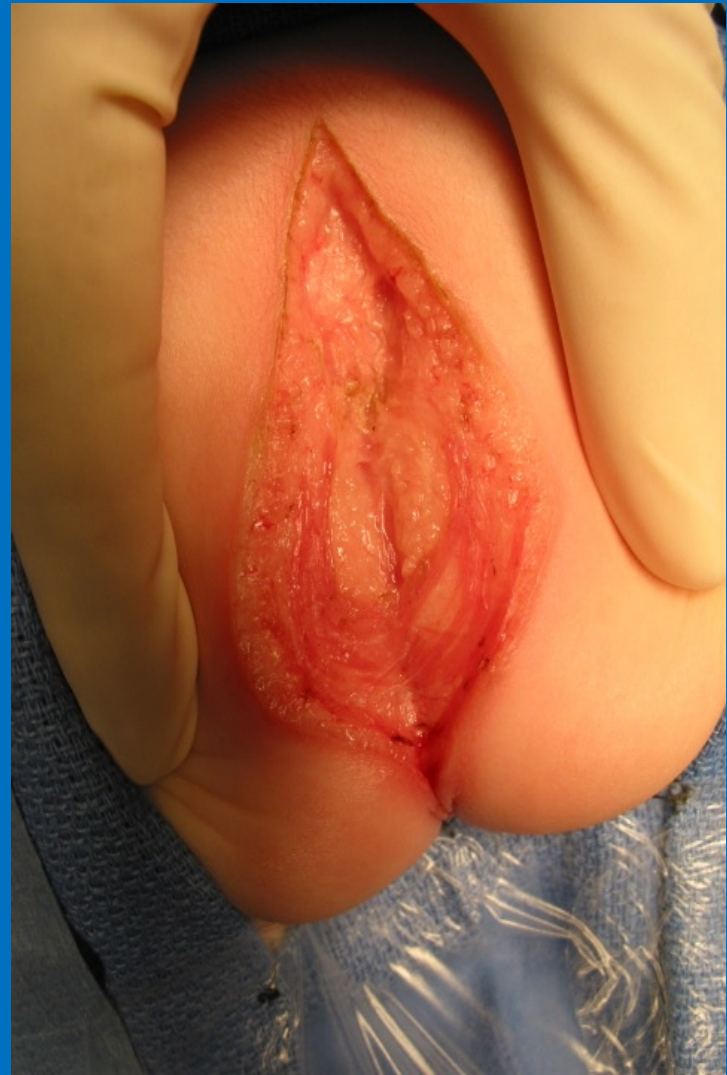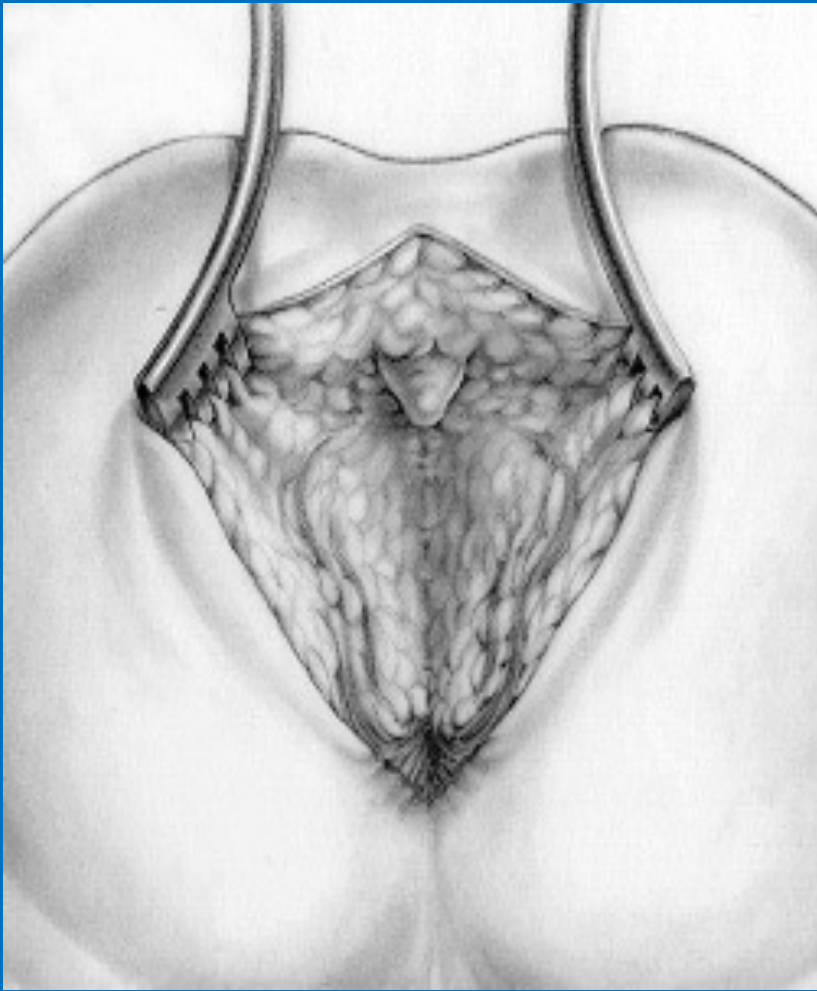
Alberto Peña – Mexico City  
1<sup>st</sup> Posterior Sagittal Approach  
for Anorectal Malformation



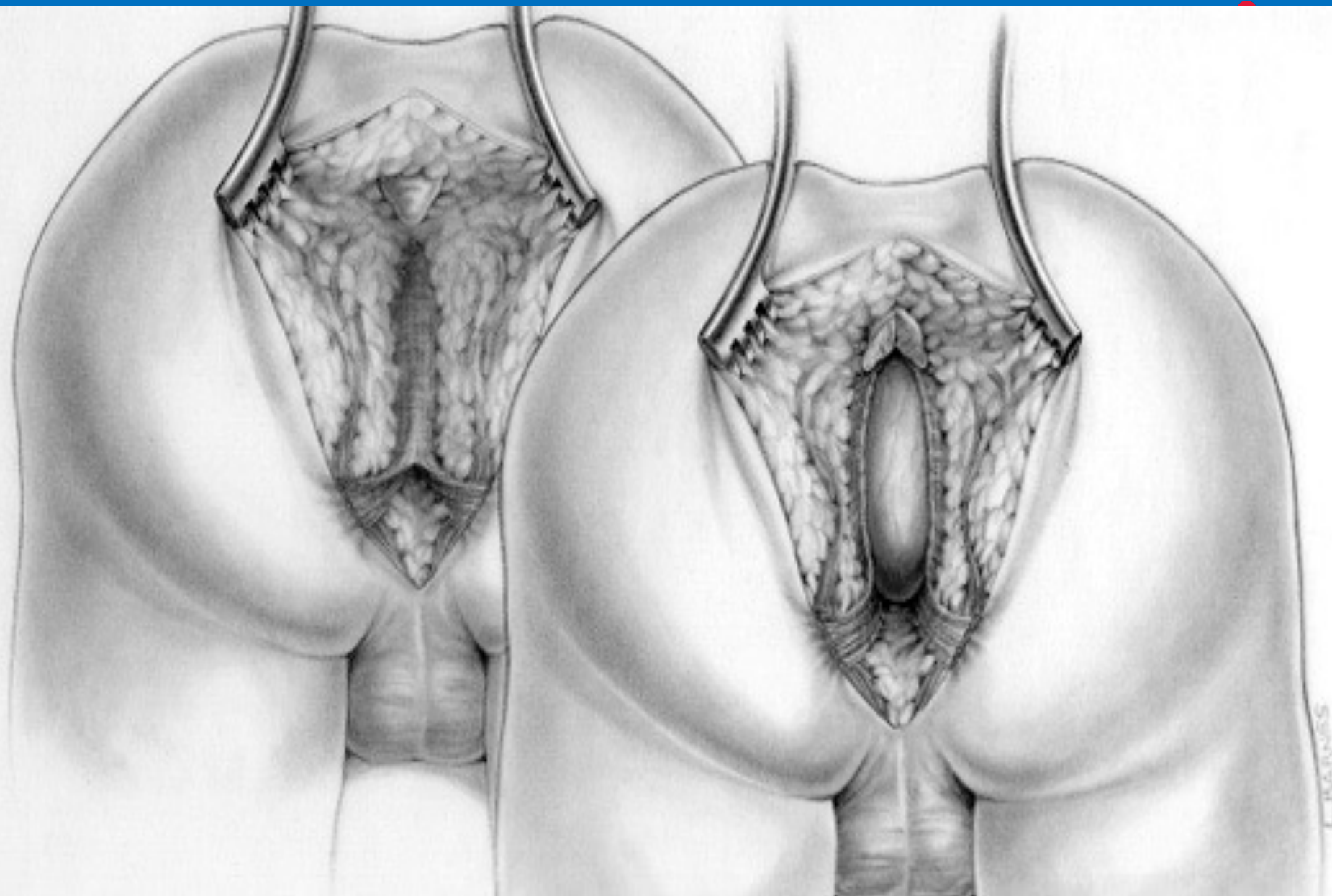


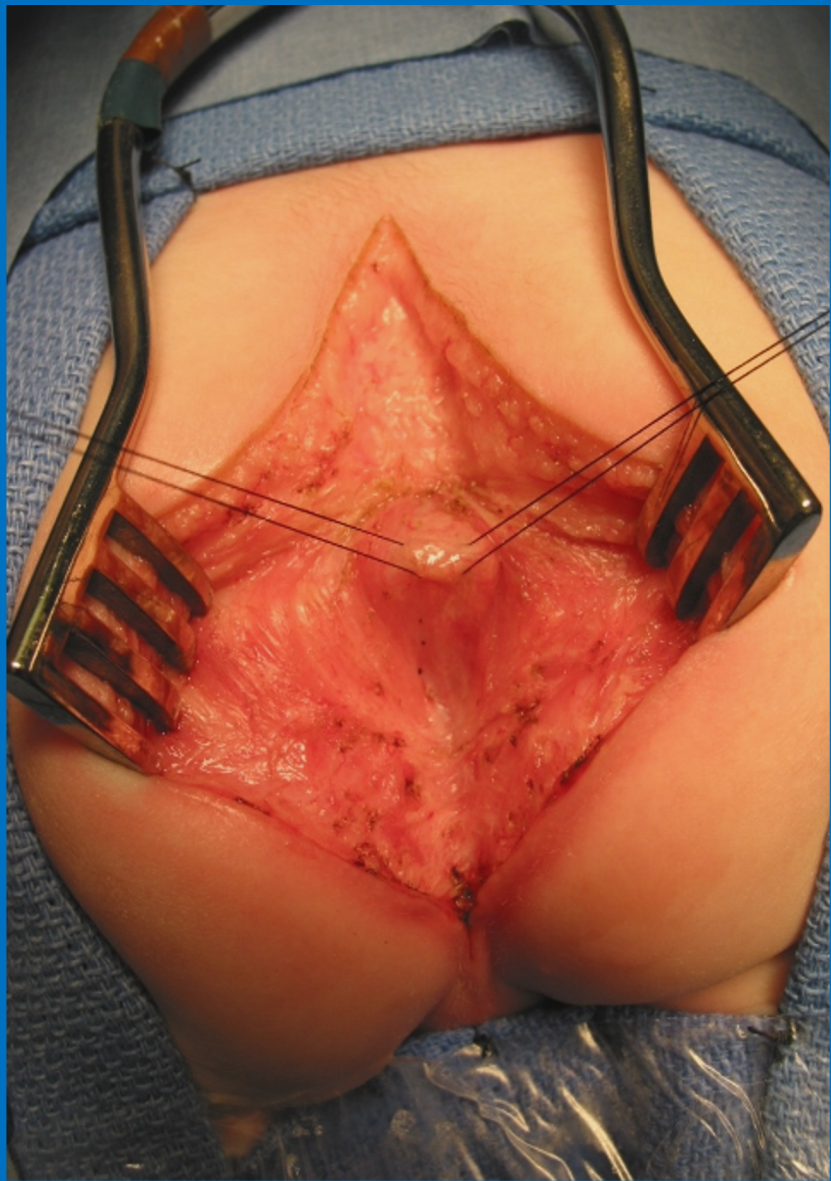
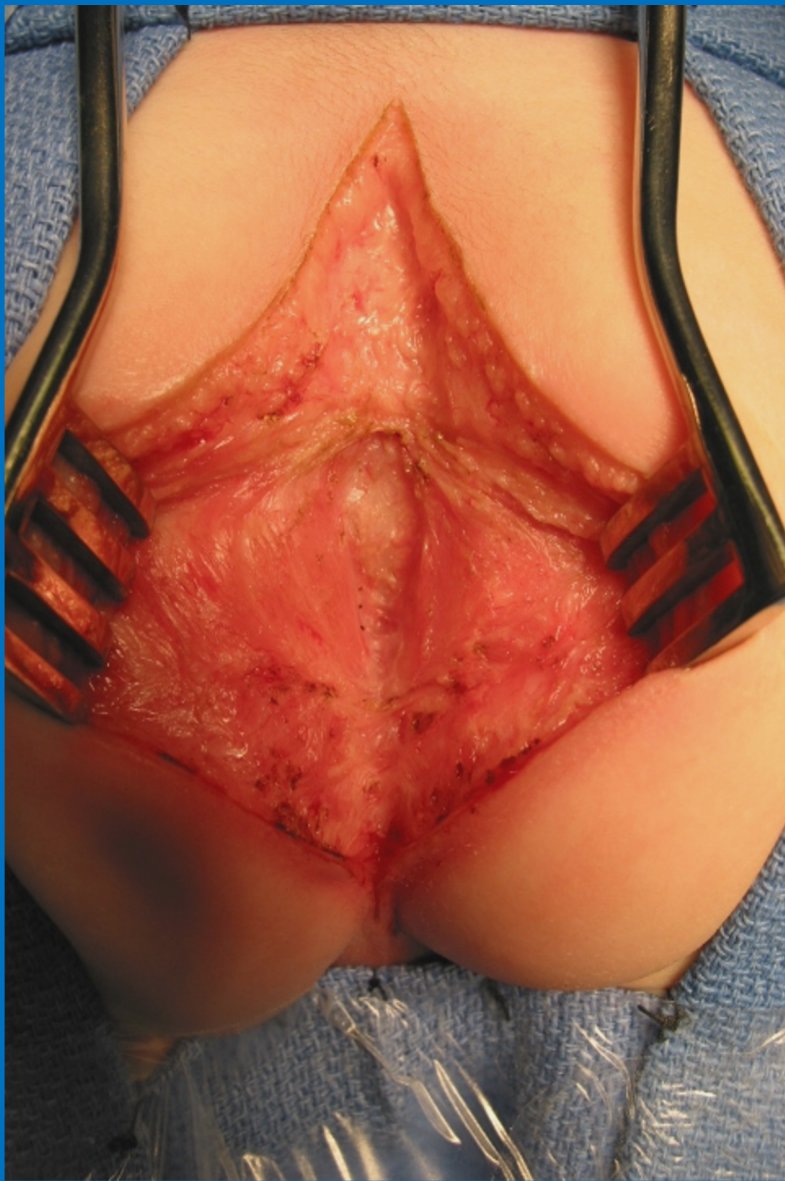INTERNATIONAL CENTER FOR  
**COLORECTAL AND  
GENITAL CARE**



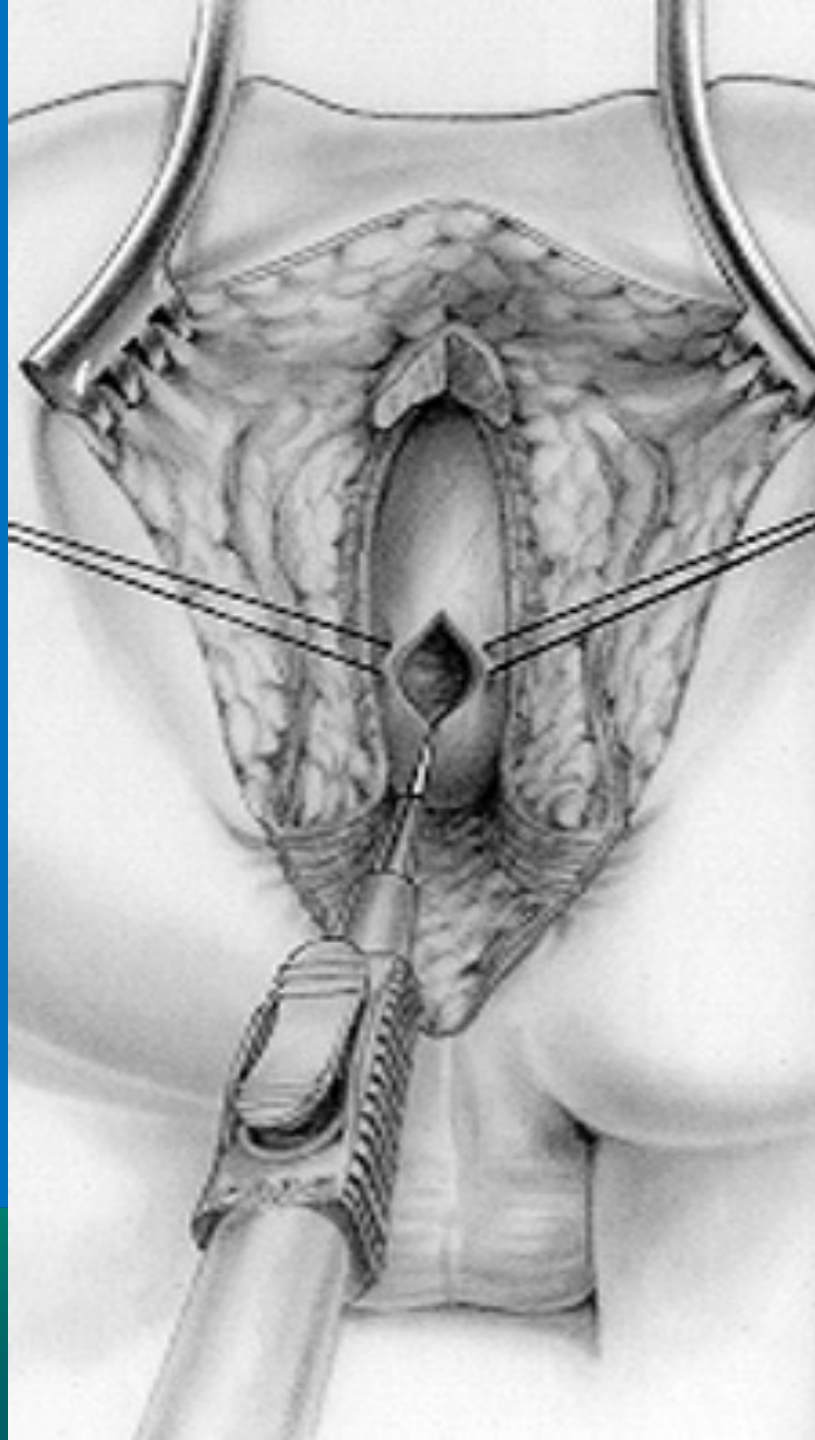




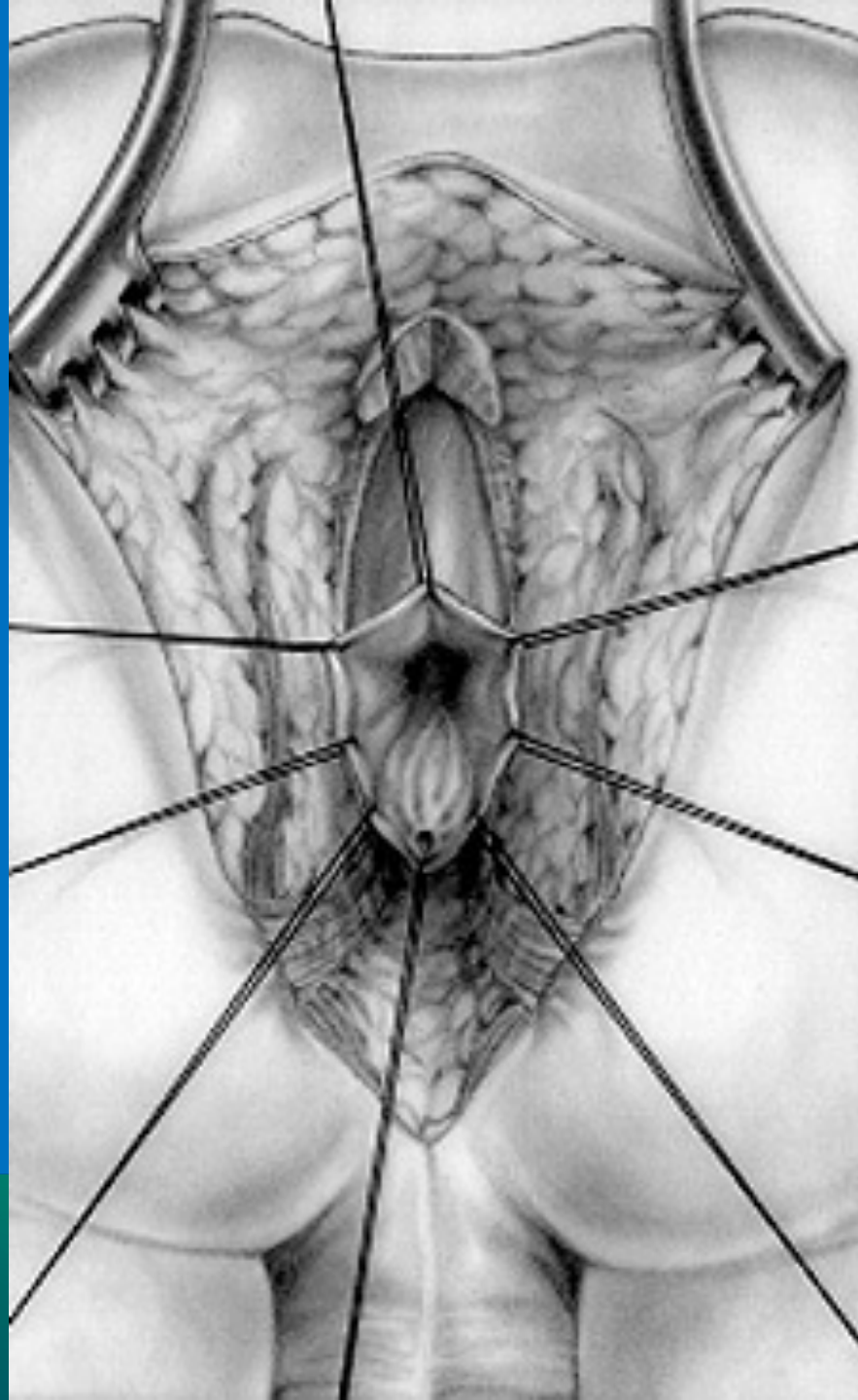






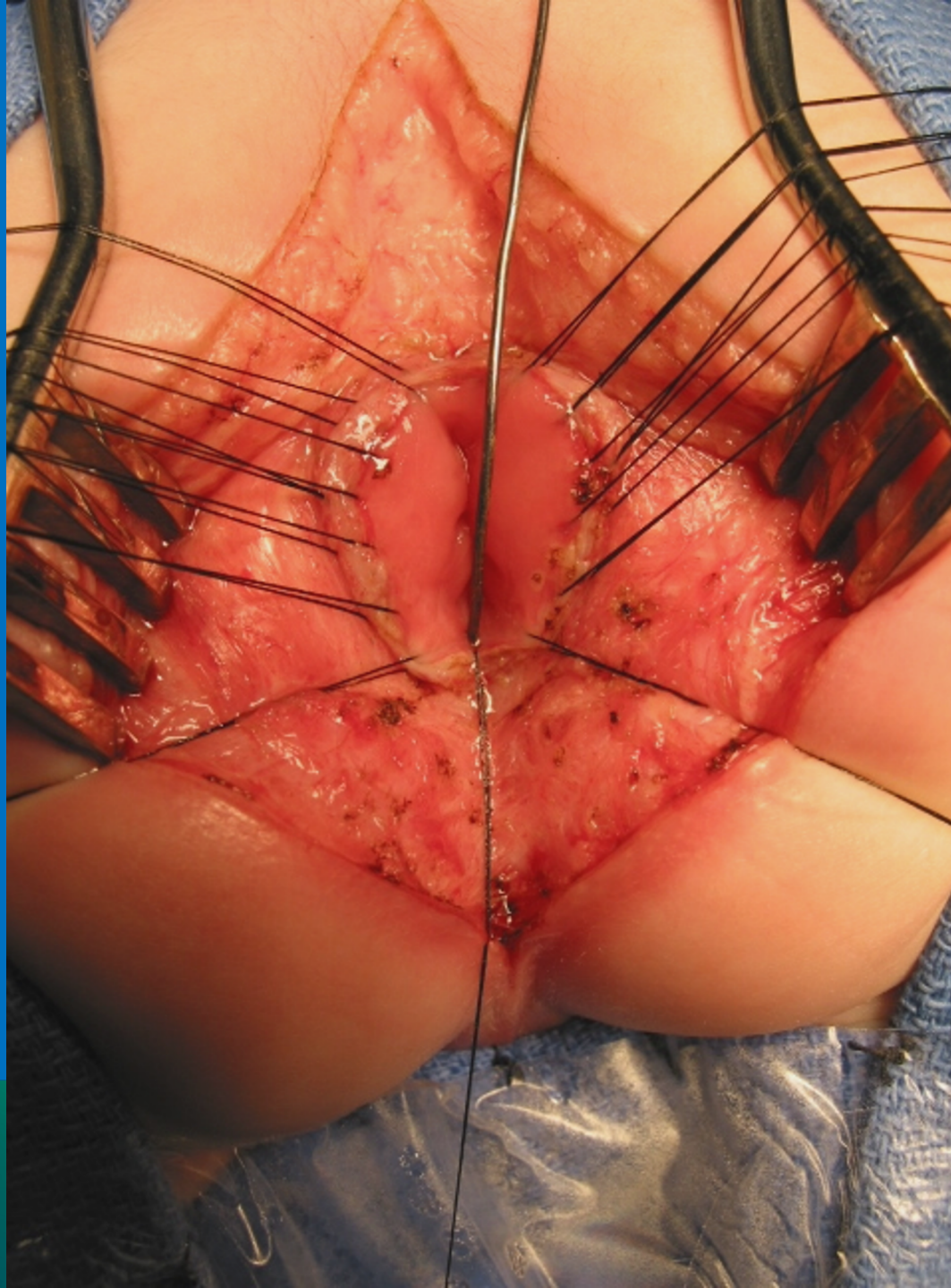


INTERNATIONAL CENTER FOR  
**COLORECTAL AND  
UROGENITAL CARE**

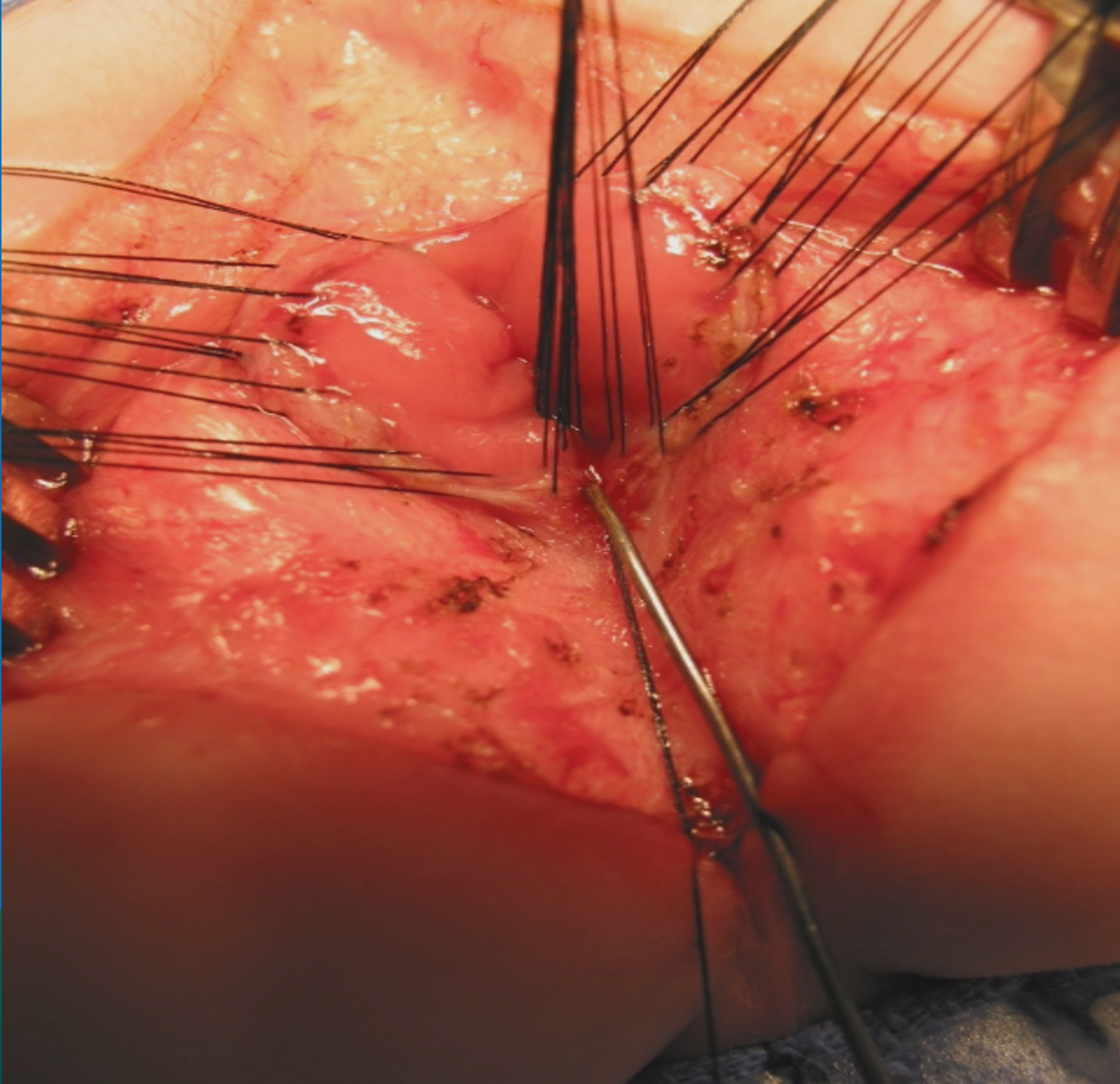


INTERNATIONAL CENTER FOR  
**COLORECTAL AND  
PROGENITAL CARE**



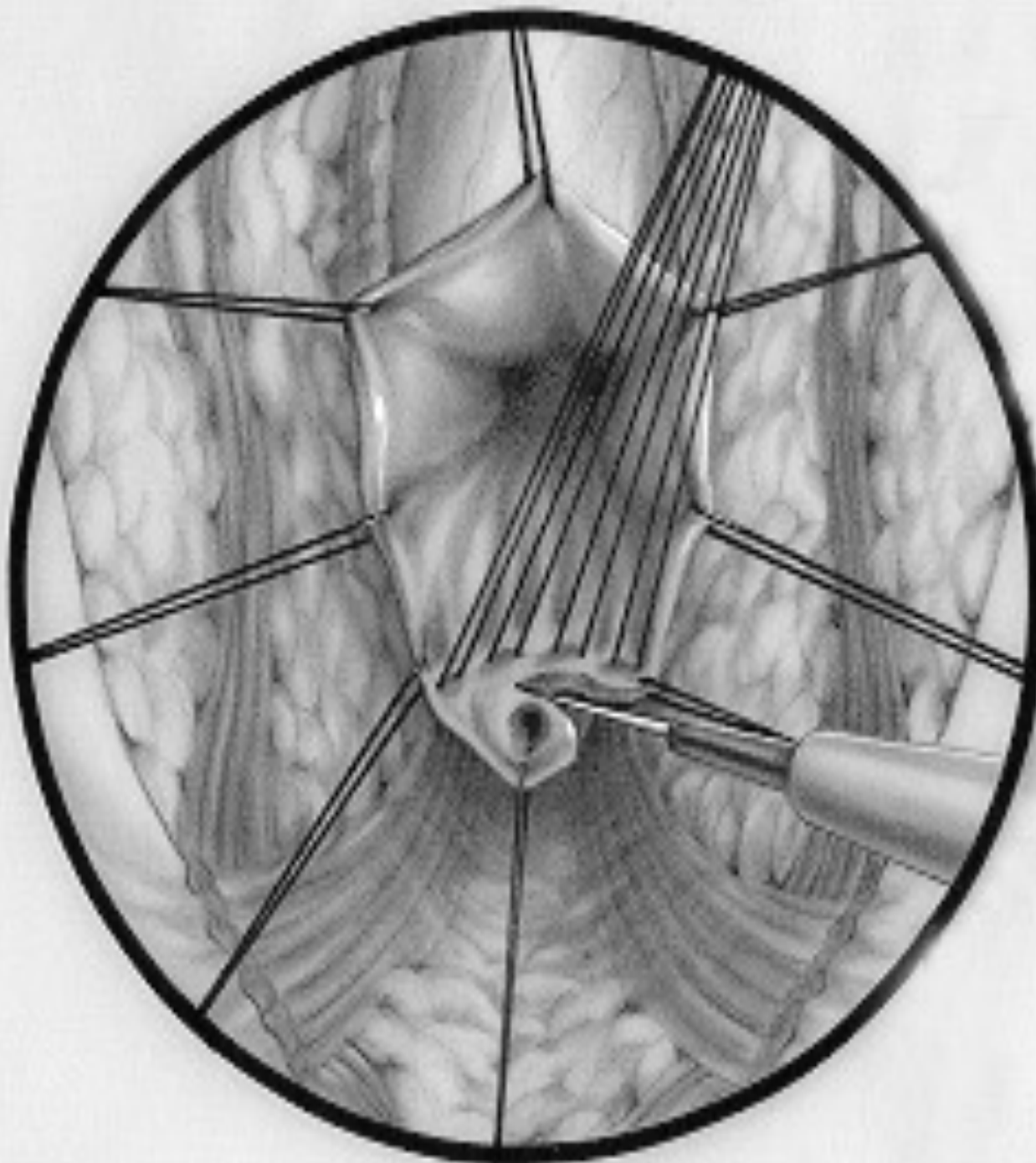


INTERNATIONAL CENTER FOR  
**RECTAL AND  
ANAL CARE**

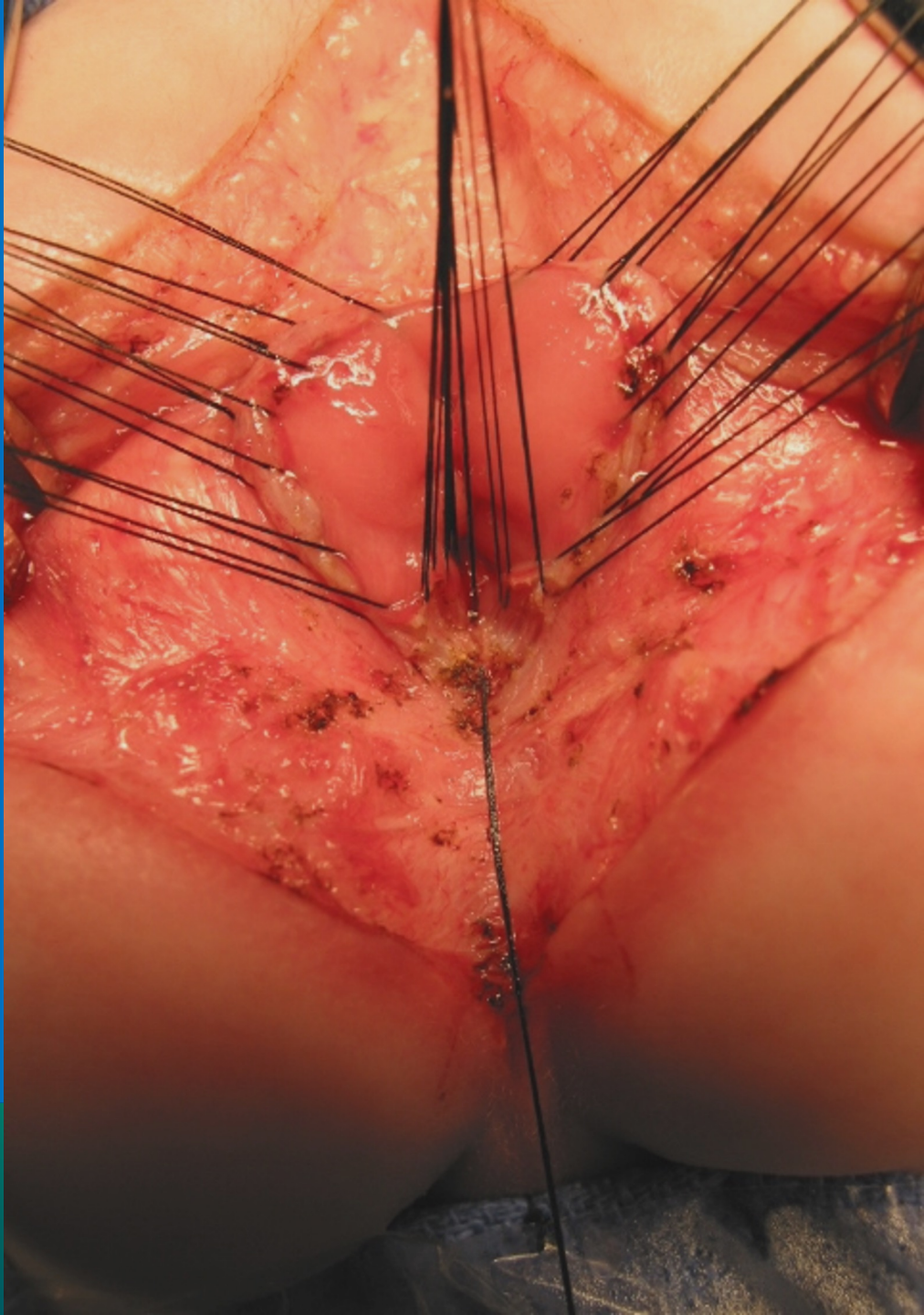


FOR  
ND  
RE



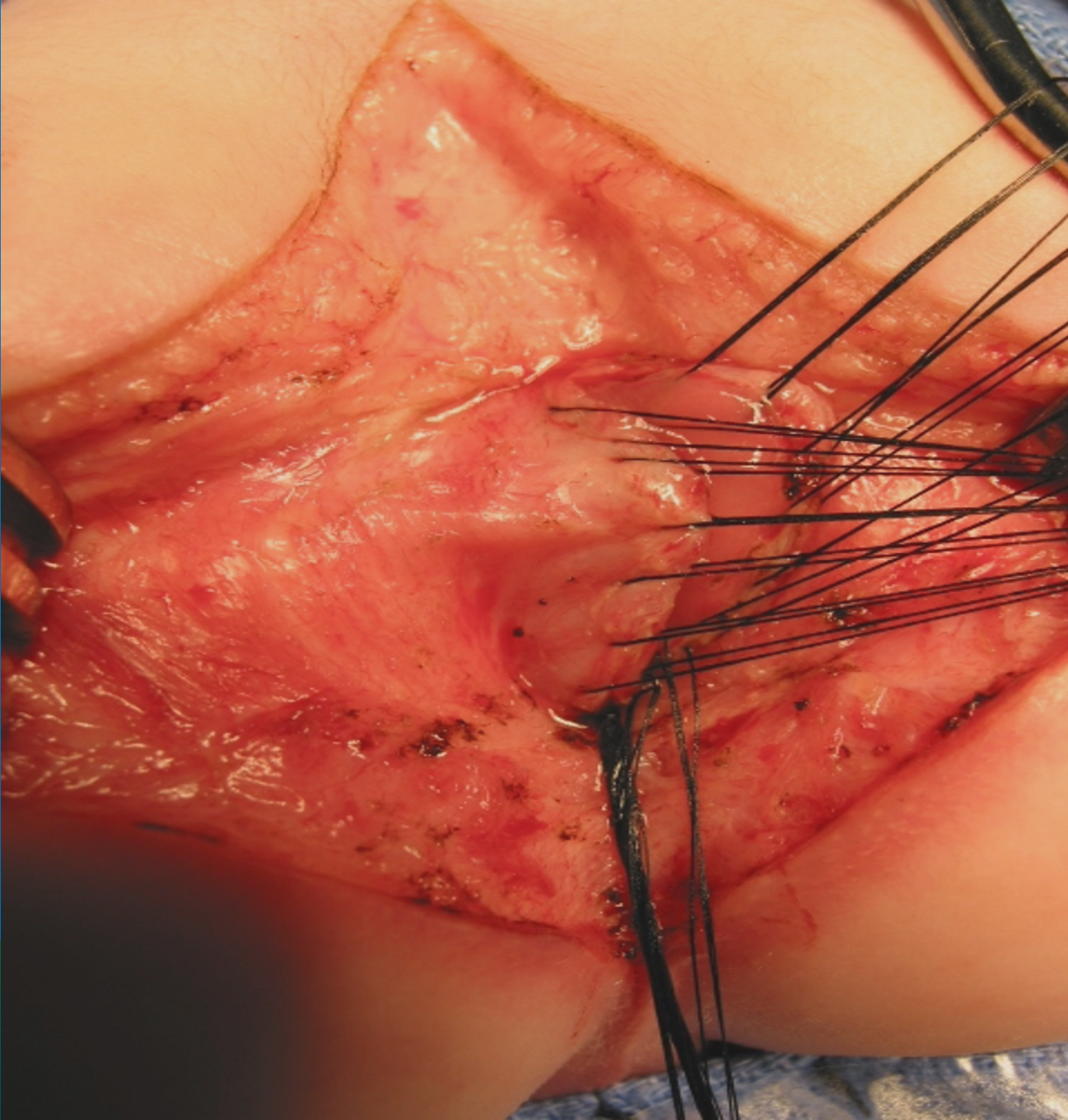


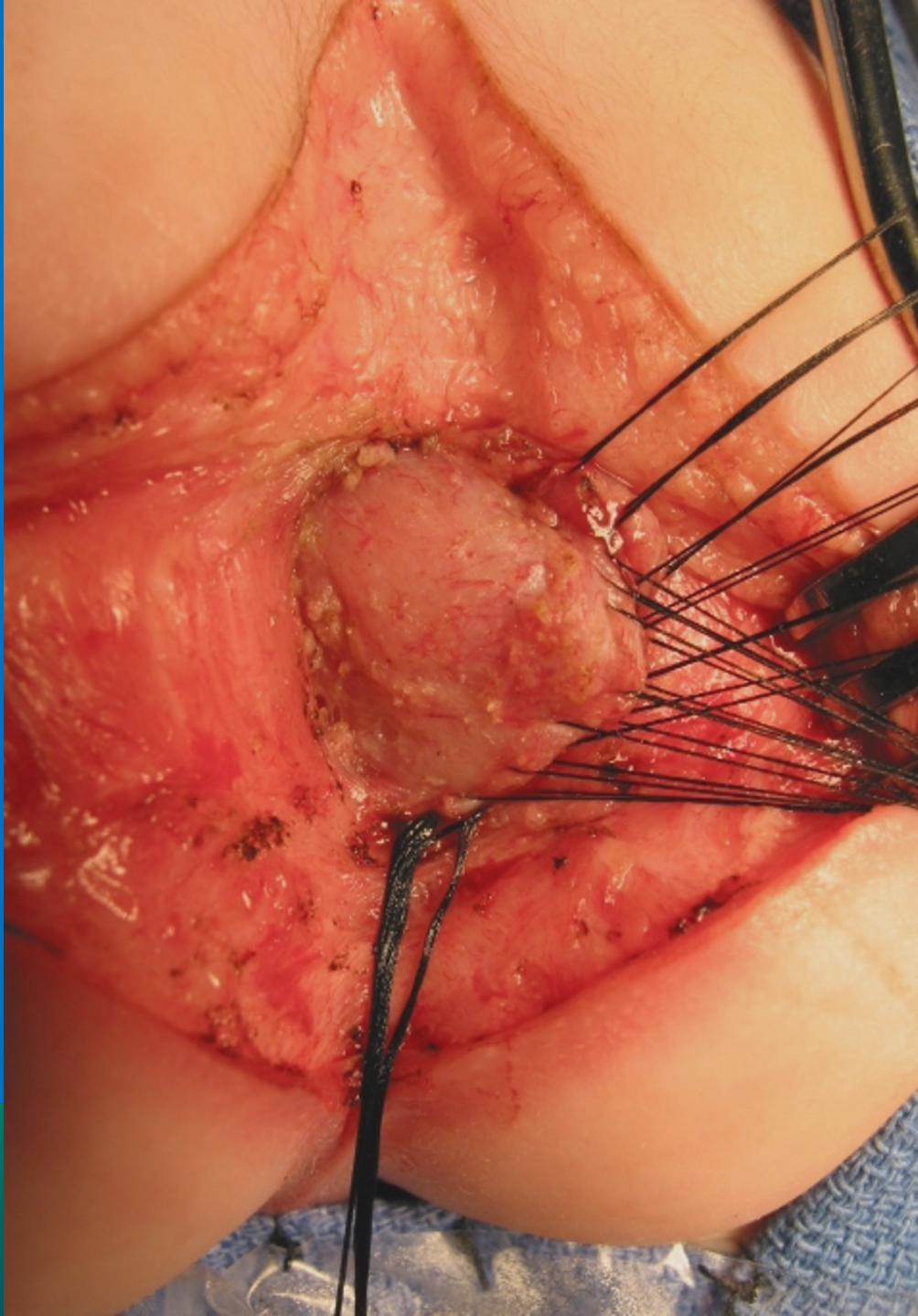
CENTER FOR  
**MENTAL AND  
BEHAVIORAL CARE**



NATIONAL CENTER FOR  
**RECTAL AND  
ANAL CARE**

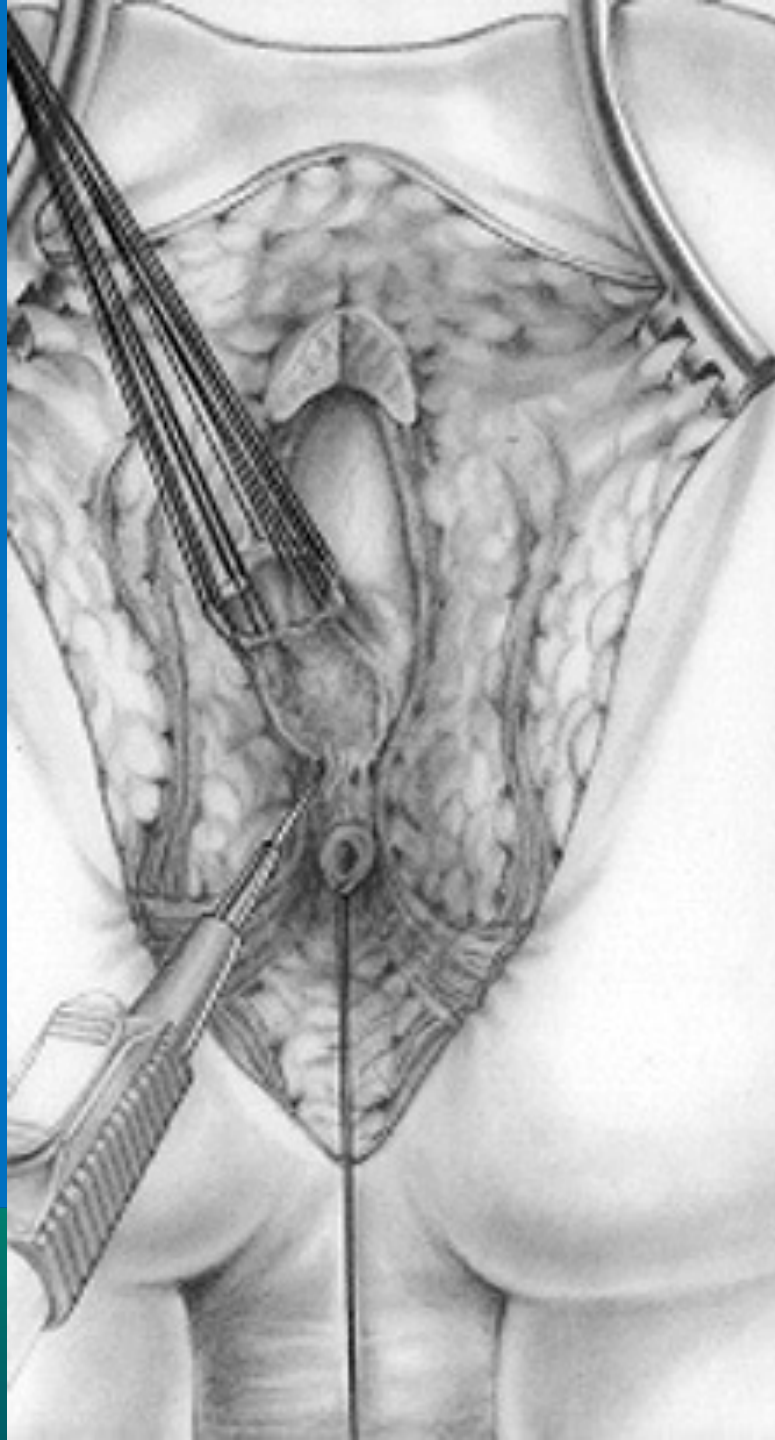






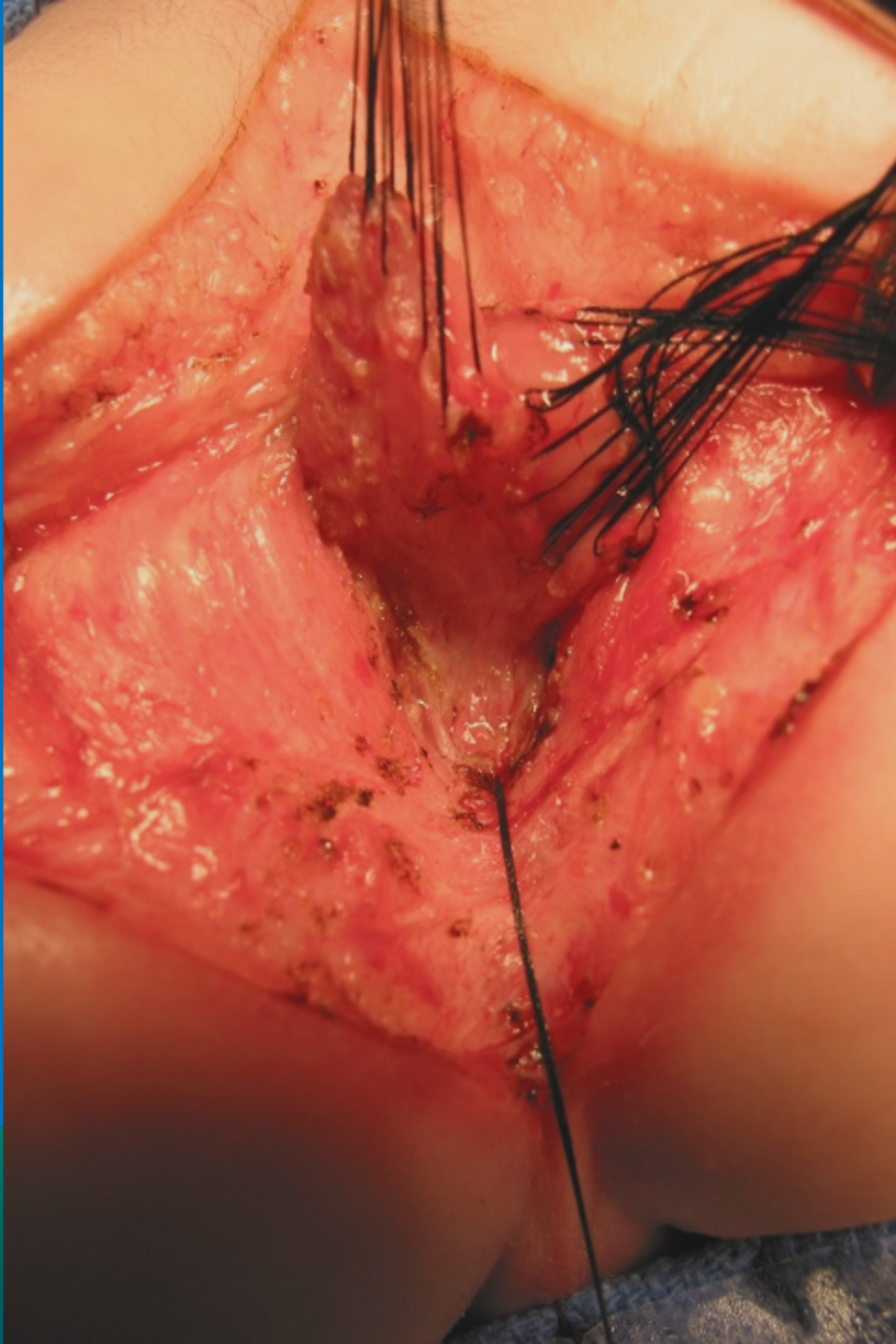
NATIONAL CENTER FOR  
**RECTAL AND  
ANAL CARE**



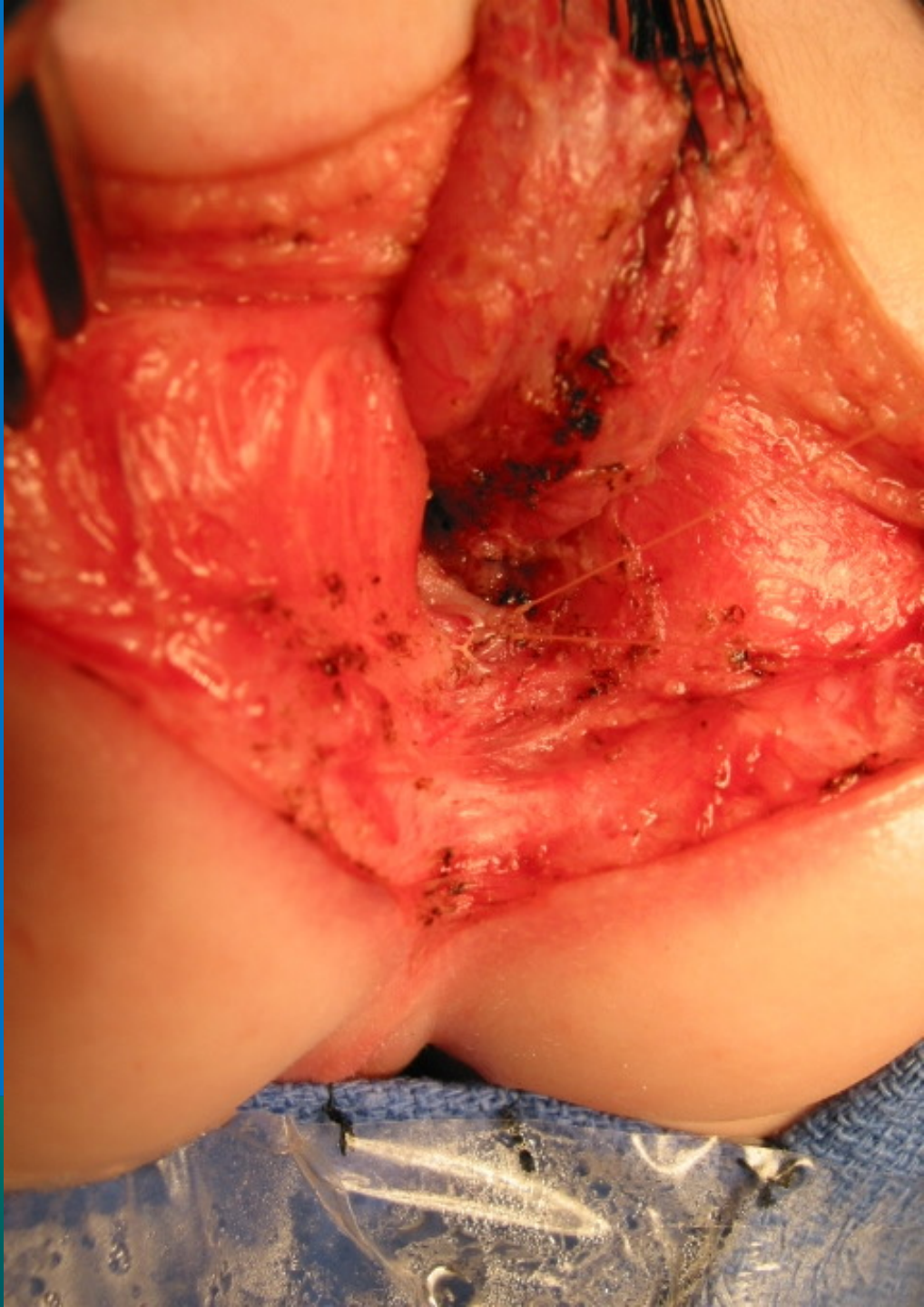

INTERNATIONAL CENTER FOR  
**COLORECTAL AND  
UROGENITAL CARE**

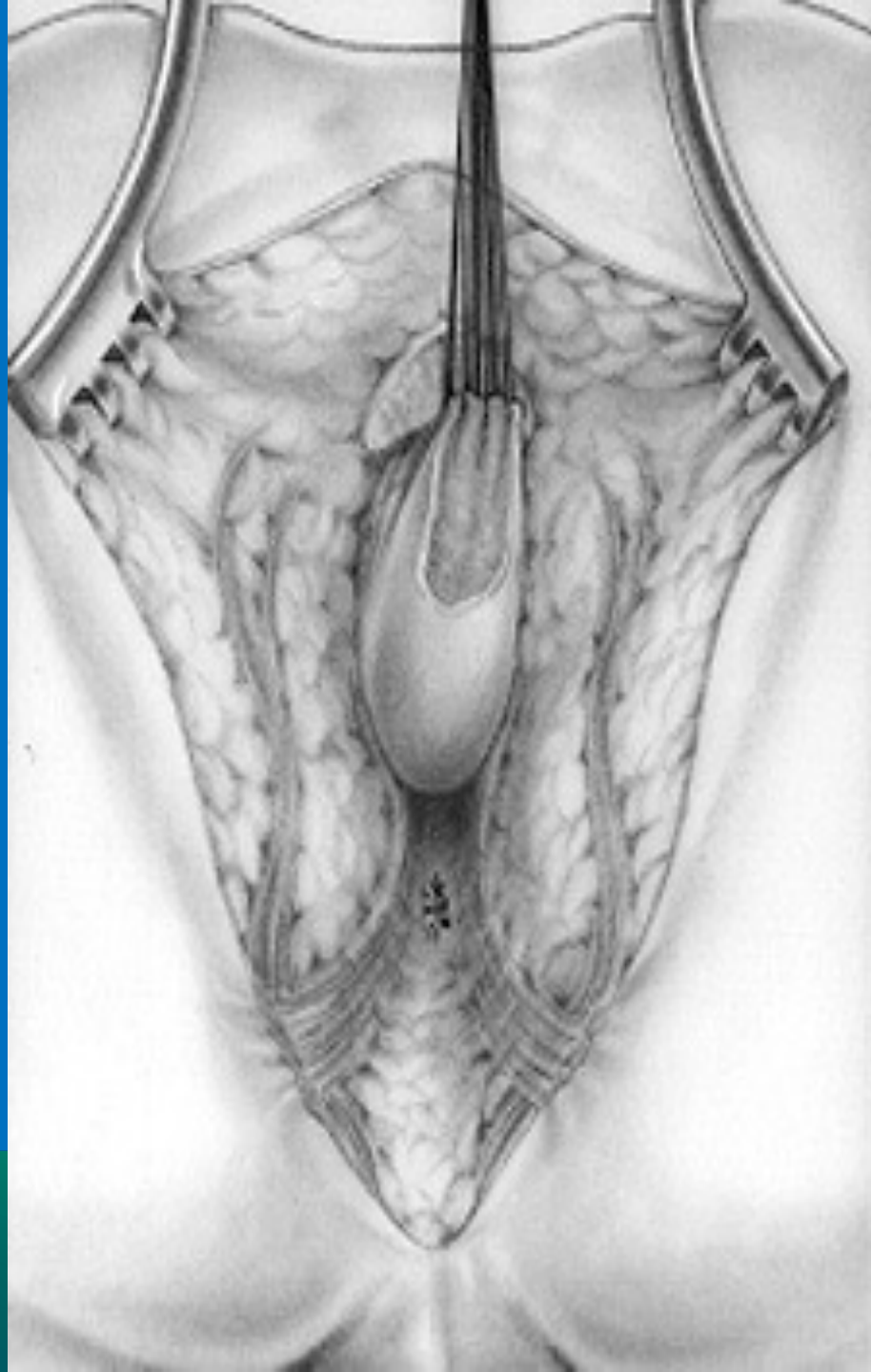




INTERNATIONAL CENTER FOR  
**OTORHINO LARYNGOLOGY AND**  
**HEAD AND NECK SURGERY**

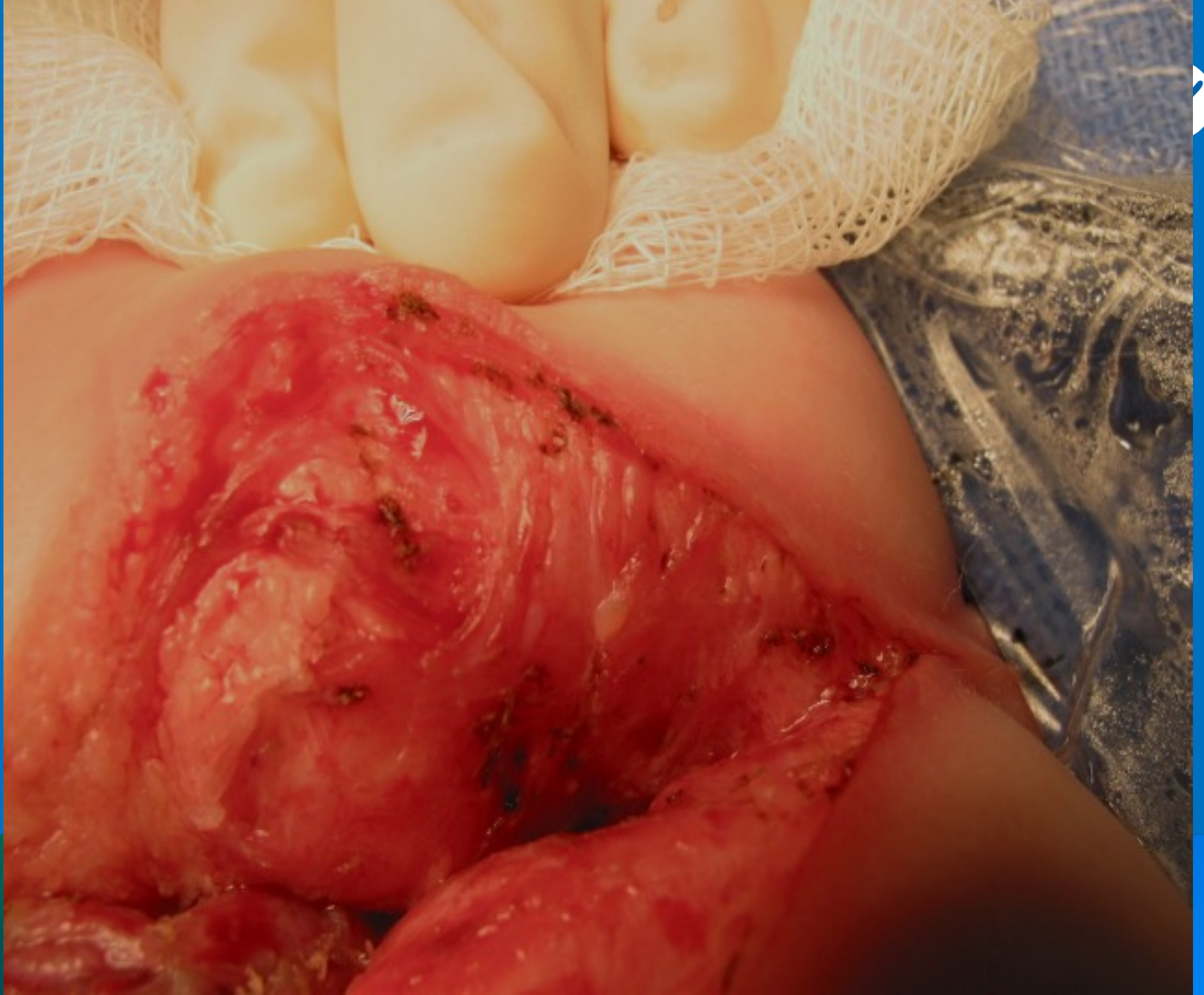

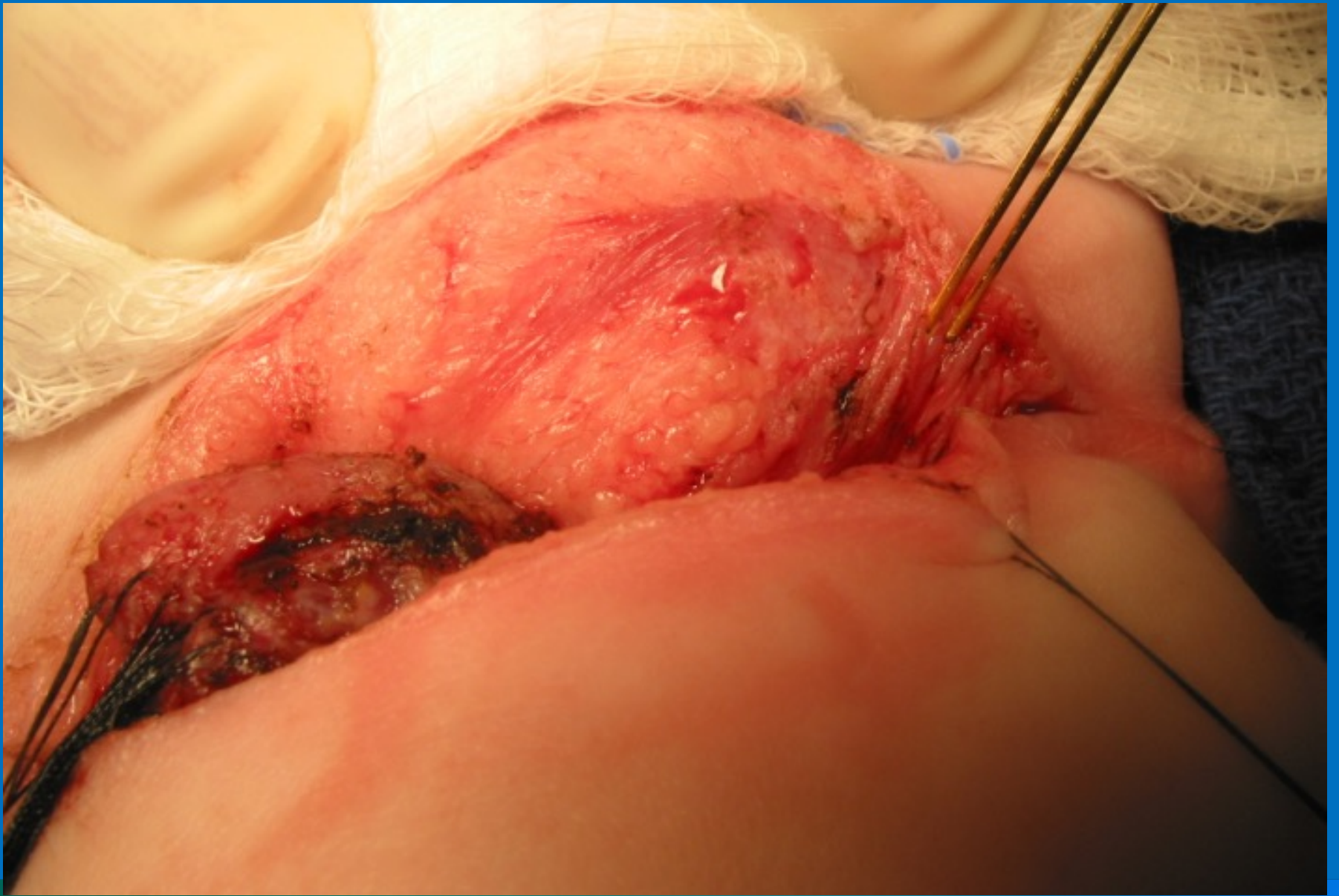
NATIONAL CENTER FOR  
**RECTAL AND  
ANAL CARE**



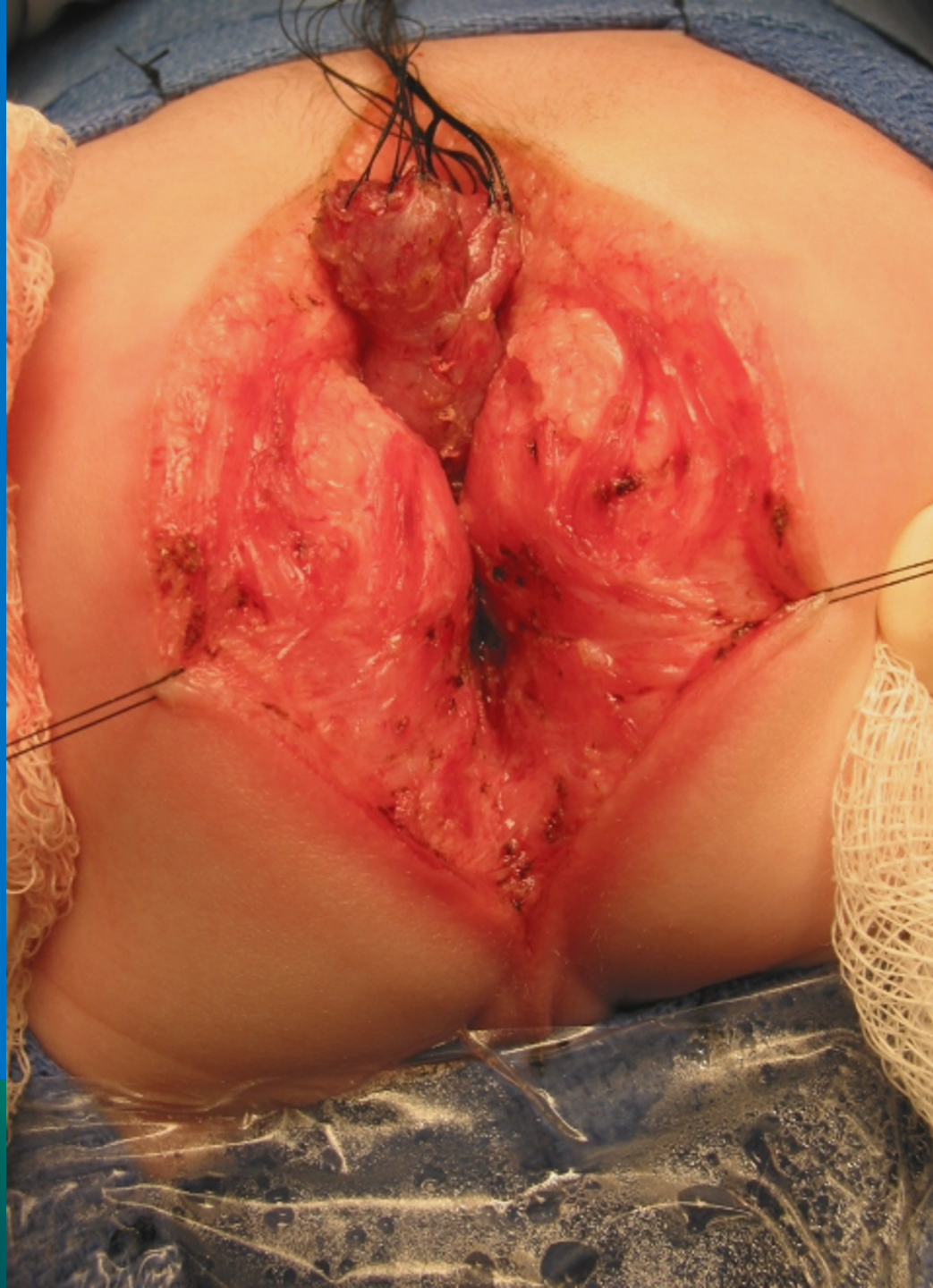
INTERNATIONAL CENTER FOR  
**COLORECTAL AND  
UROGENITAL CARE**



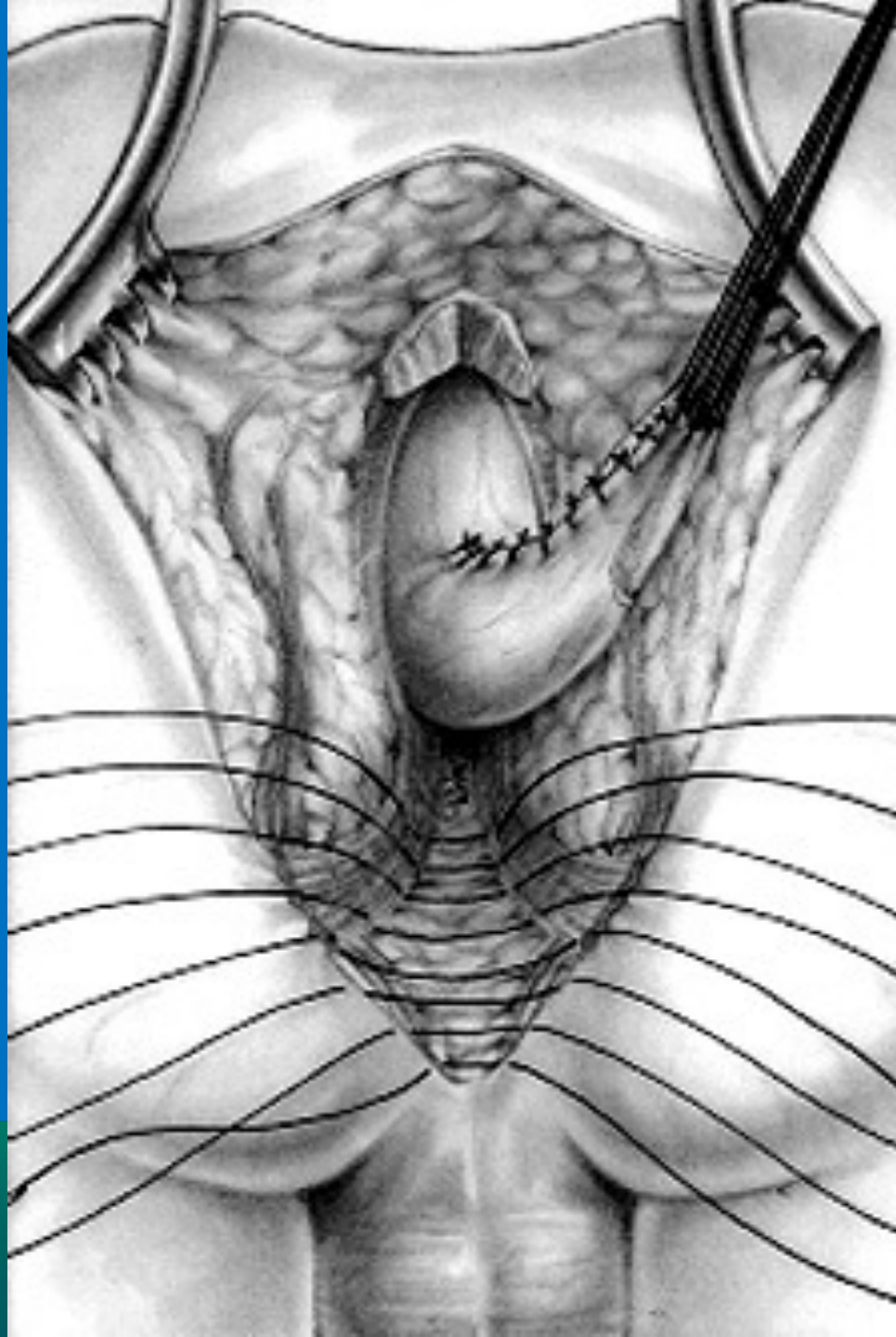






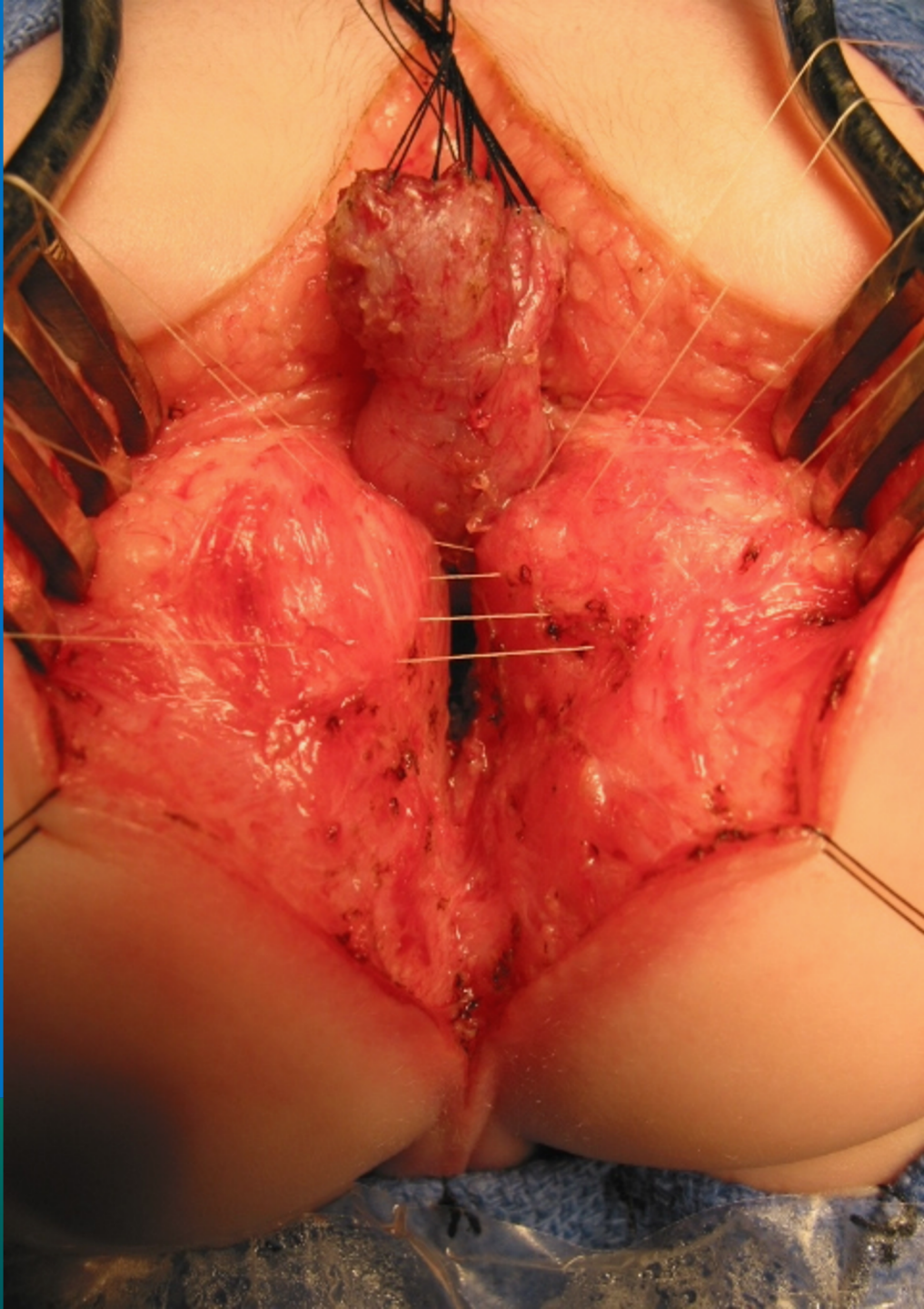


INTERNATIONAL CENTER FOR  
**COLORECTAL AND  
GENITAL CARE**

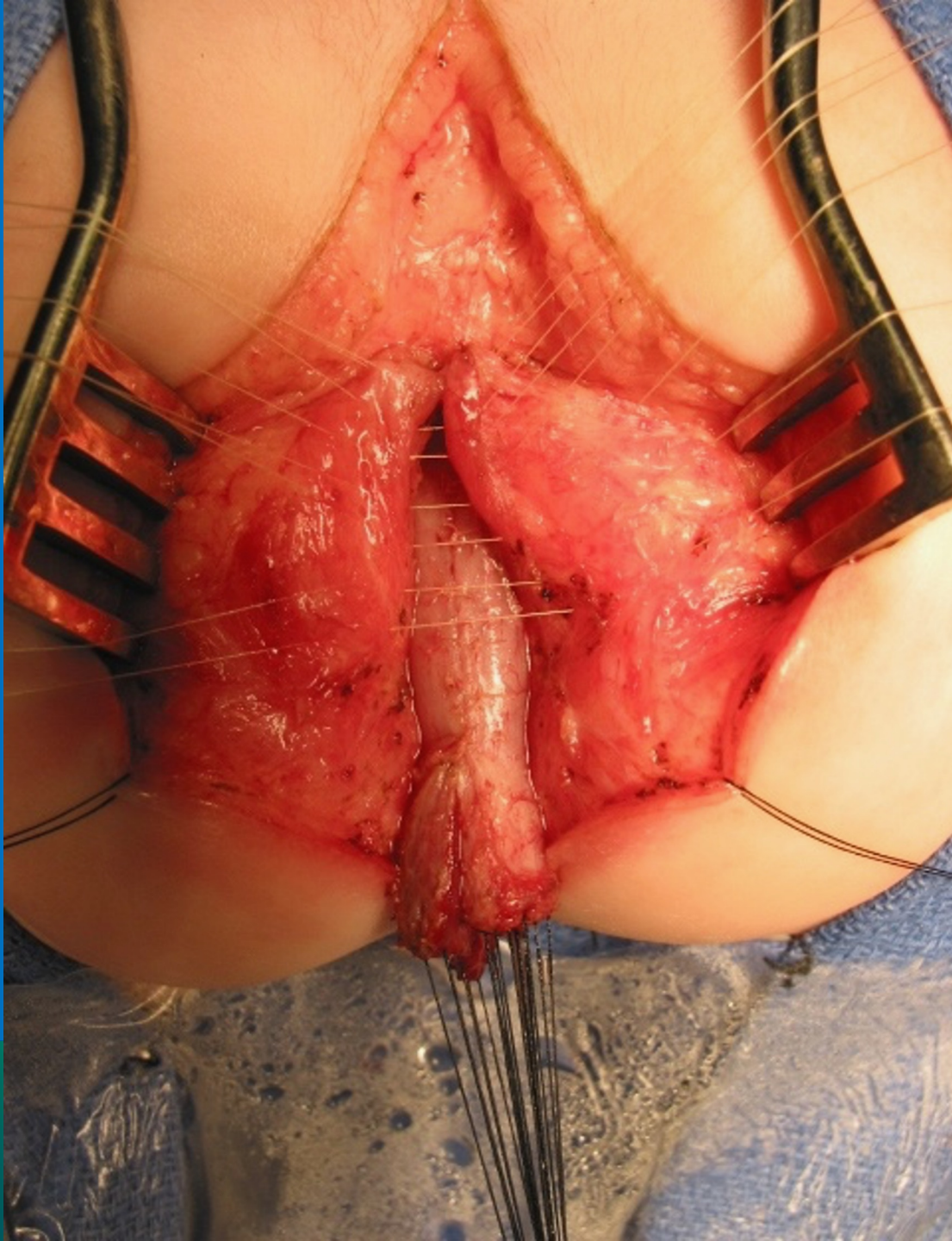


INTERNATIONAL CENTER FOR  
**OTORHINO LARYNGOLOGY AND**  
**HEAD AND NECK SURGERY**



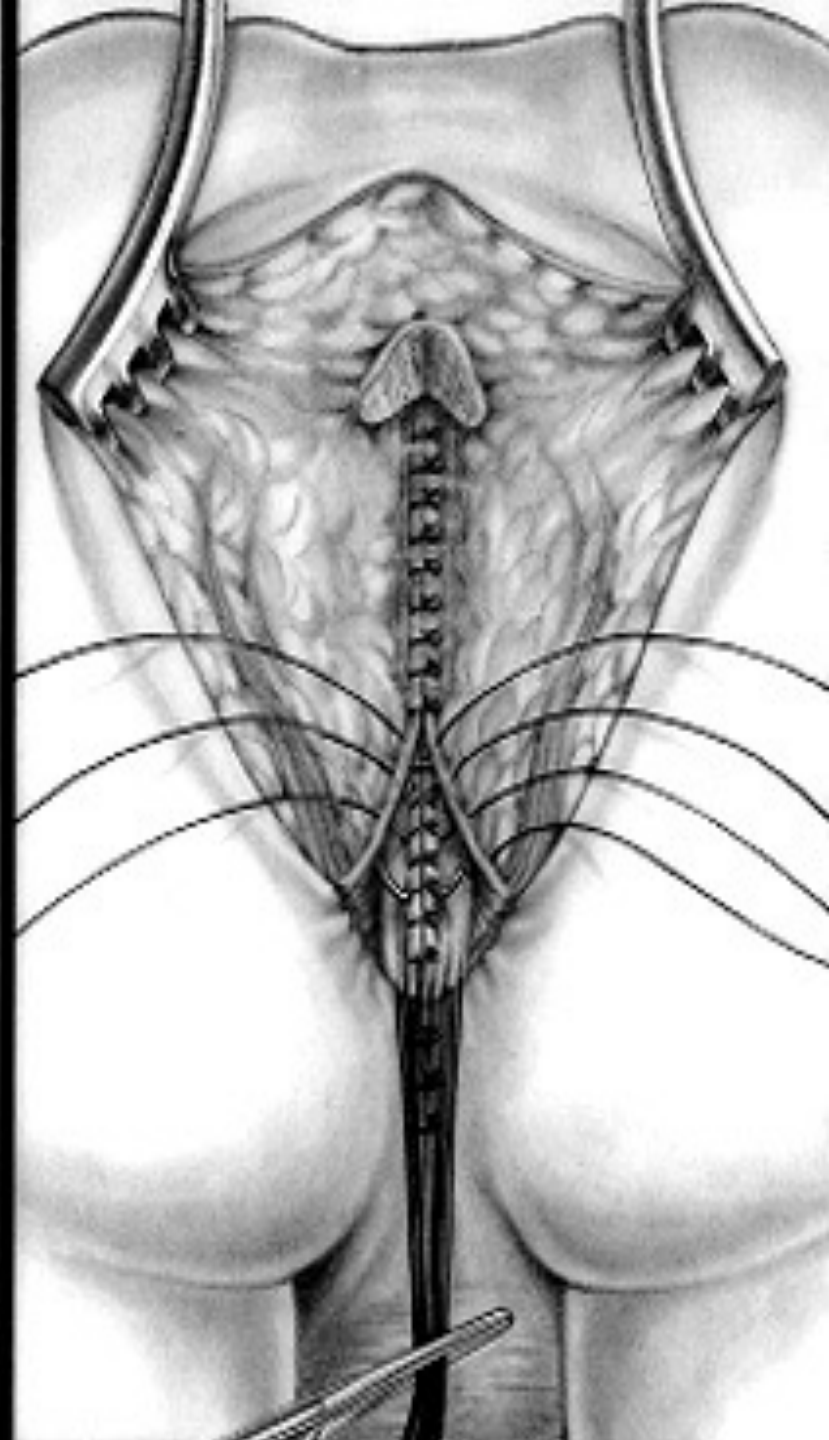
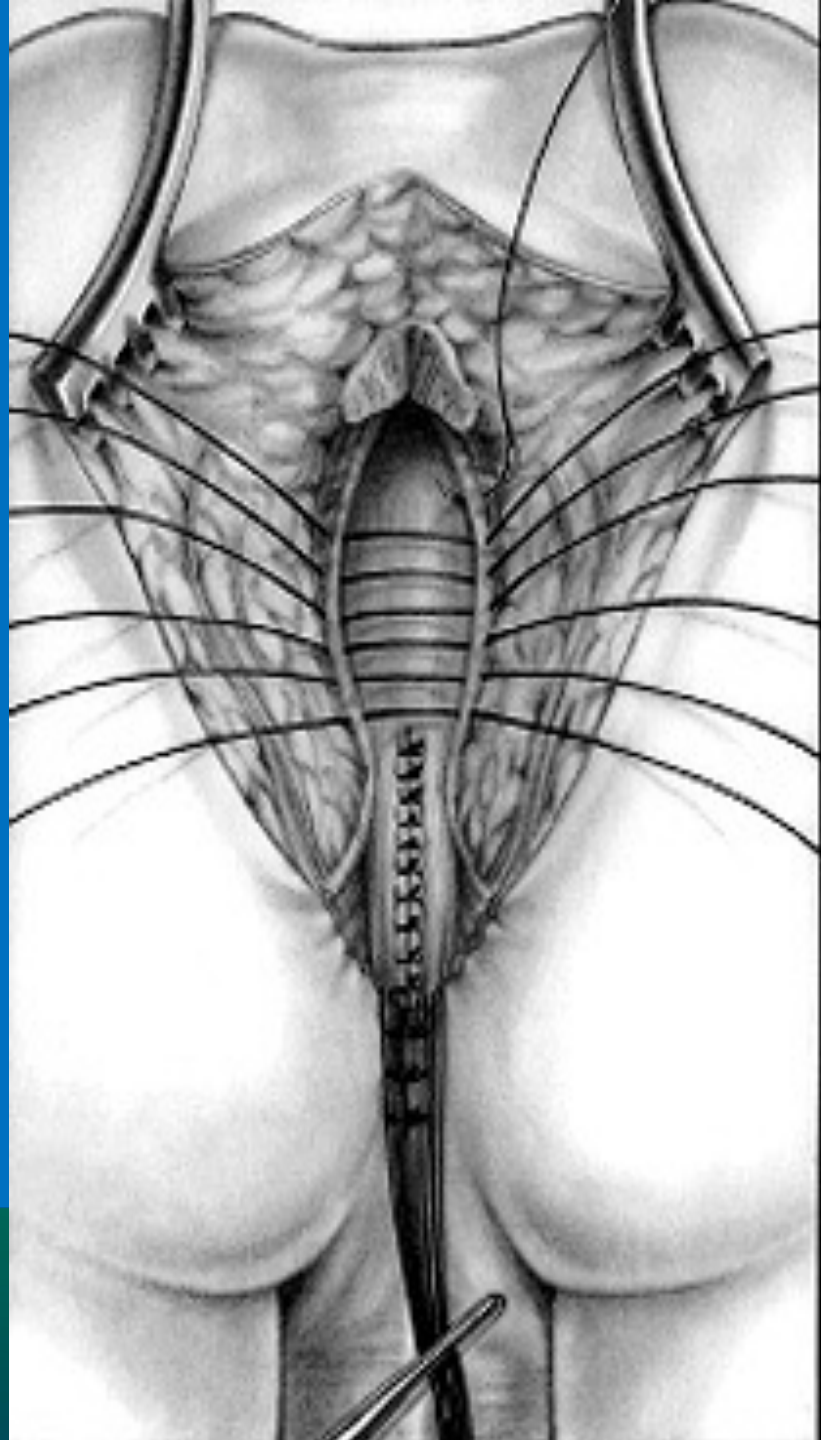


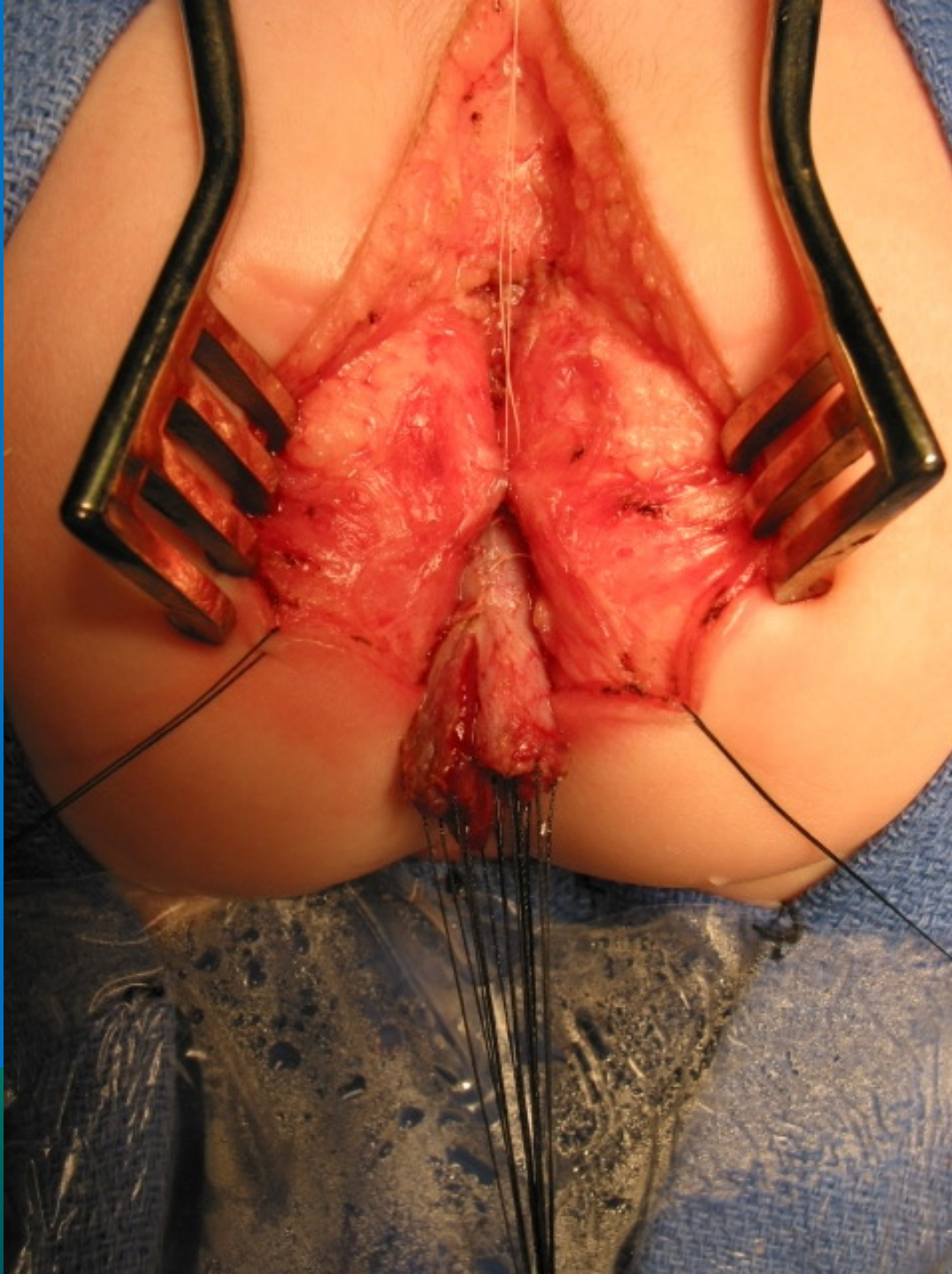NATIONAL CENTER FOR  
**COLORECTAL AND  
GENITAL CARE**



NATIONAL CENTER FOR  
**RECTAL AND  
ANAL CARE**

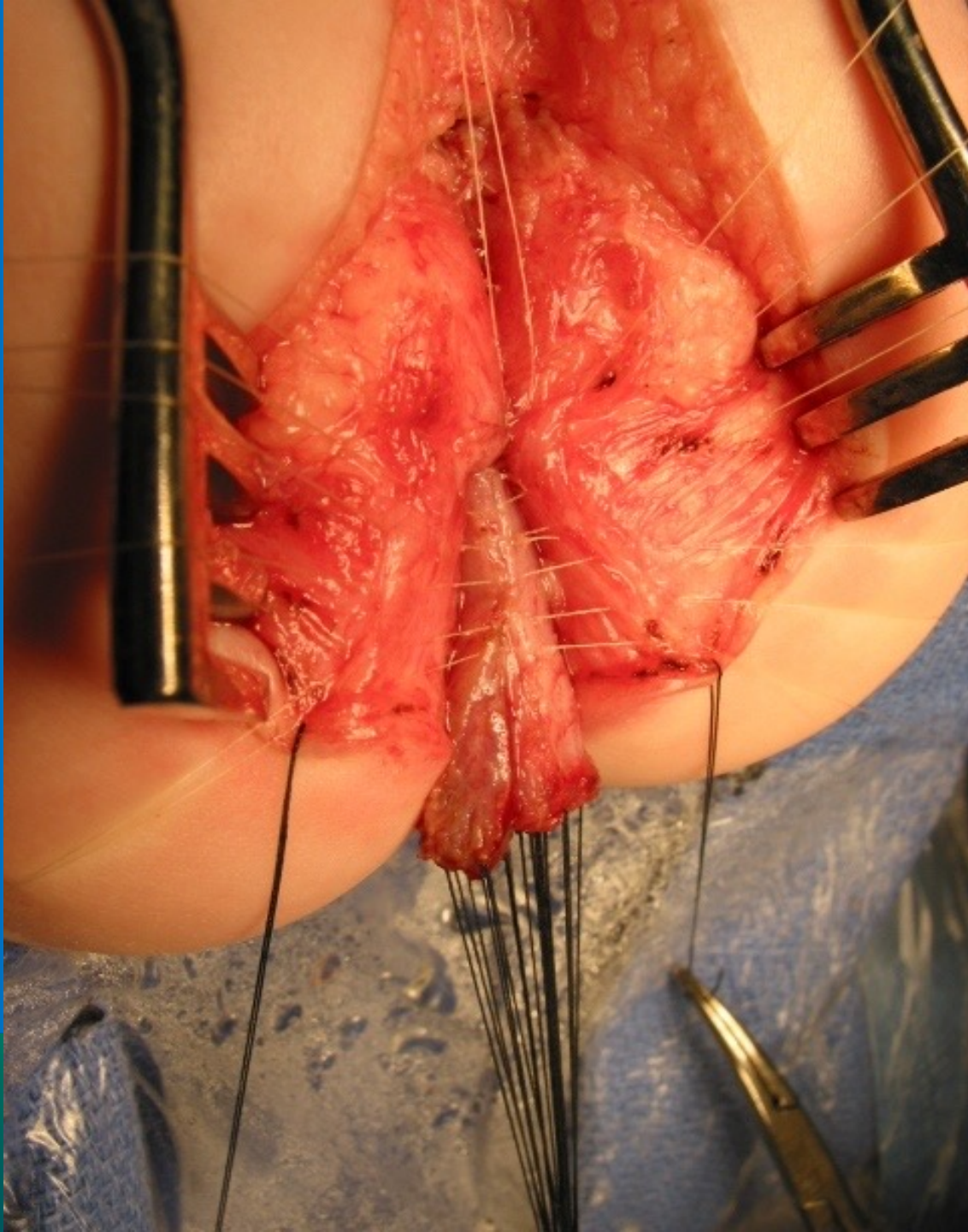




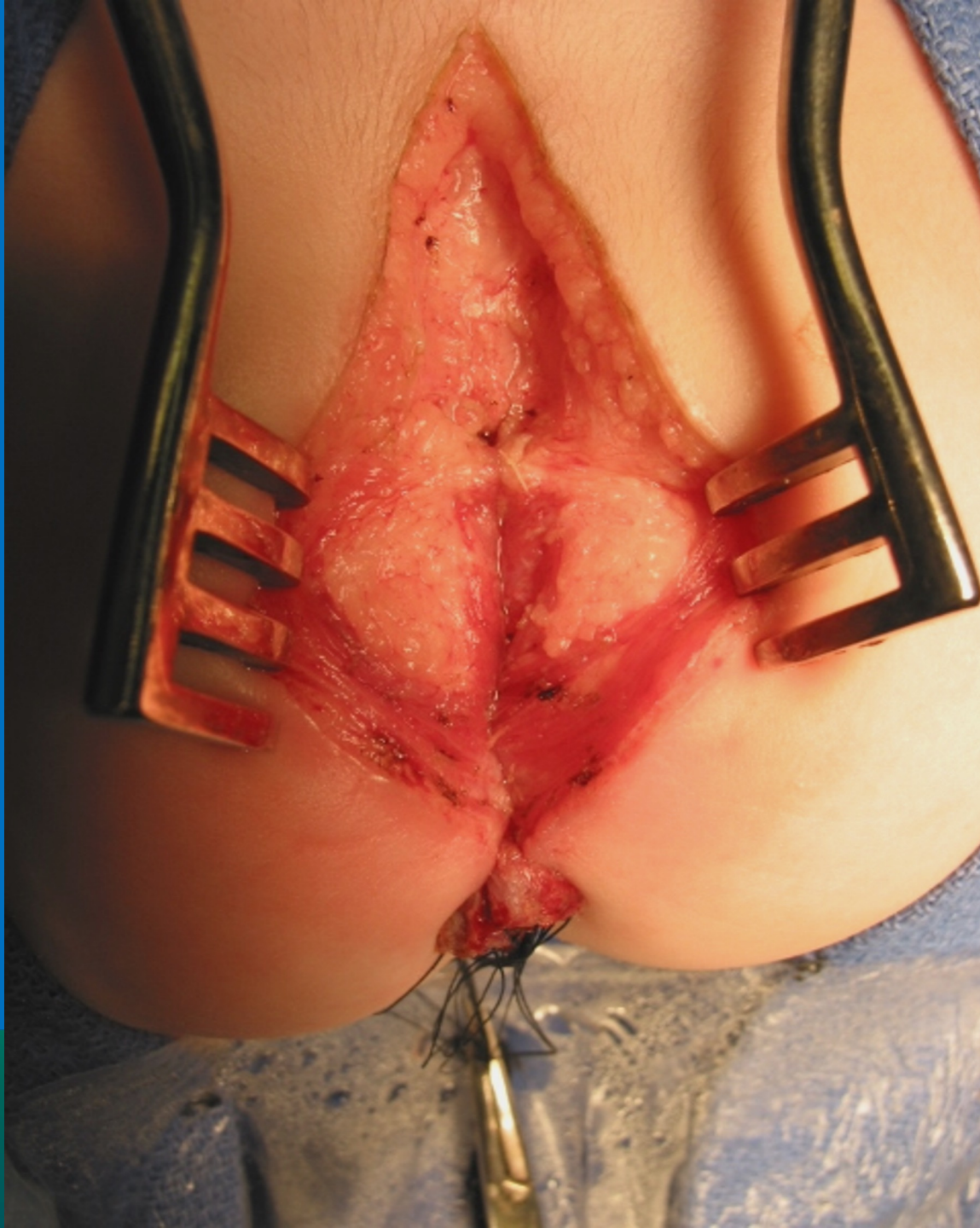

INTERNATIONAL CENTER FOR  
**RECTAL AND  
ANAL CARE**



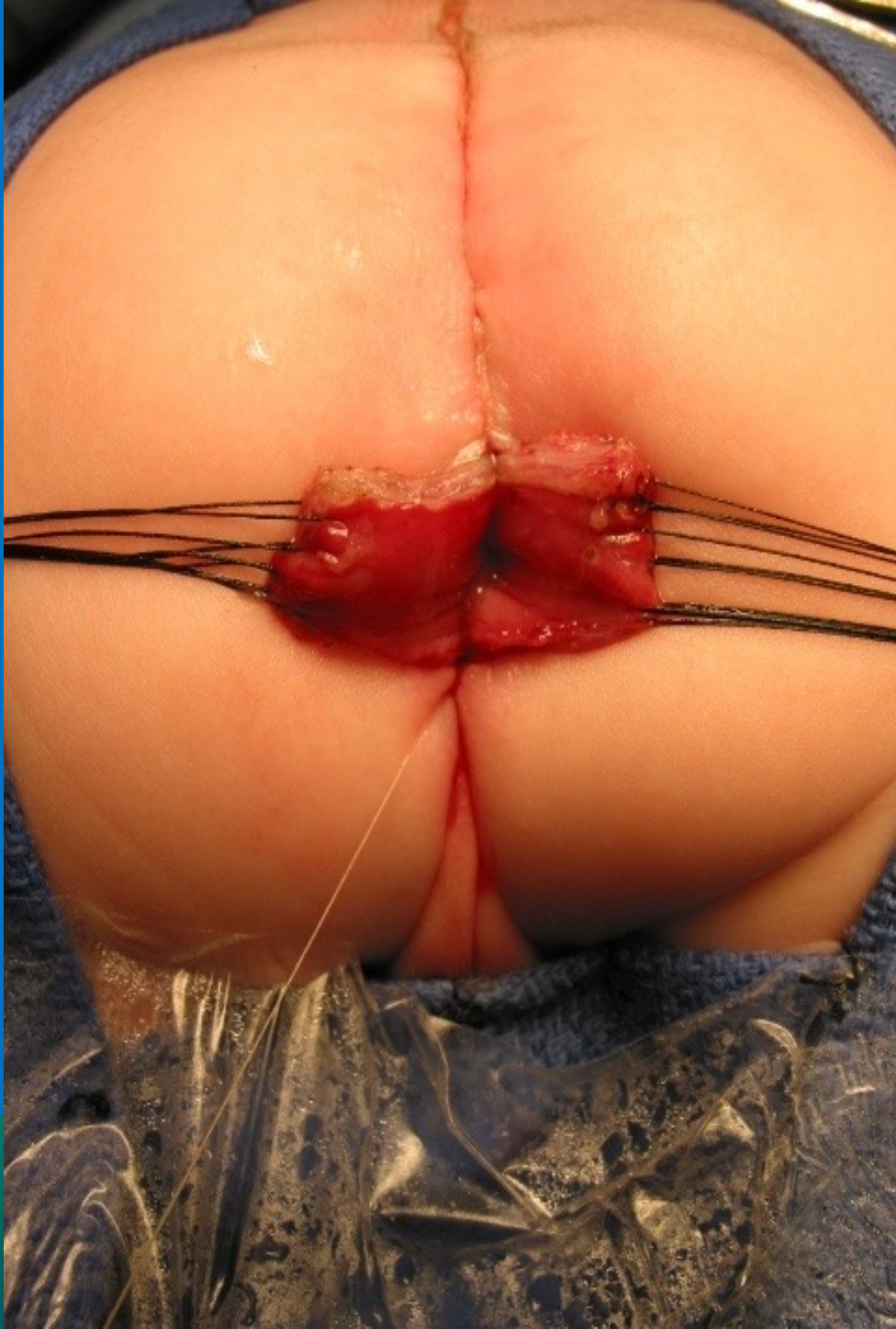

NATIONAL CENTER FOR  
**HEAD AND NECK**  
**CANCER** |  
**RESEARCH AND**  
**Clinical CARE**



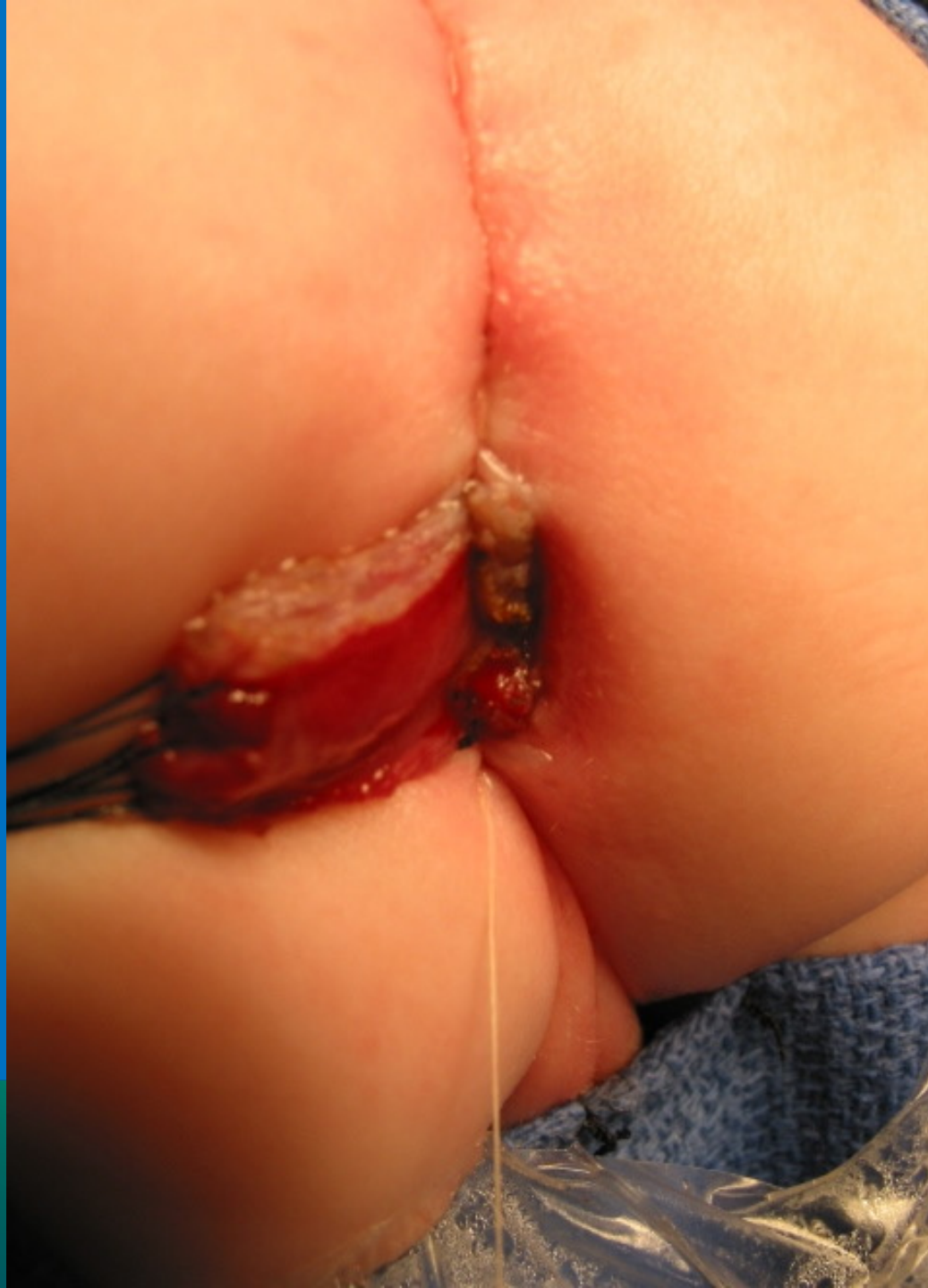NATIONAL CENTER FOR  
**RECTAL AND**  
**ANAL CARE**



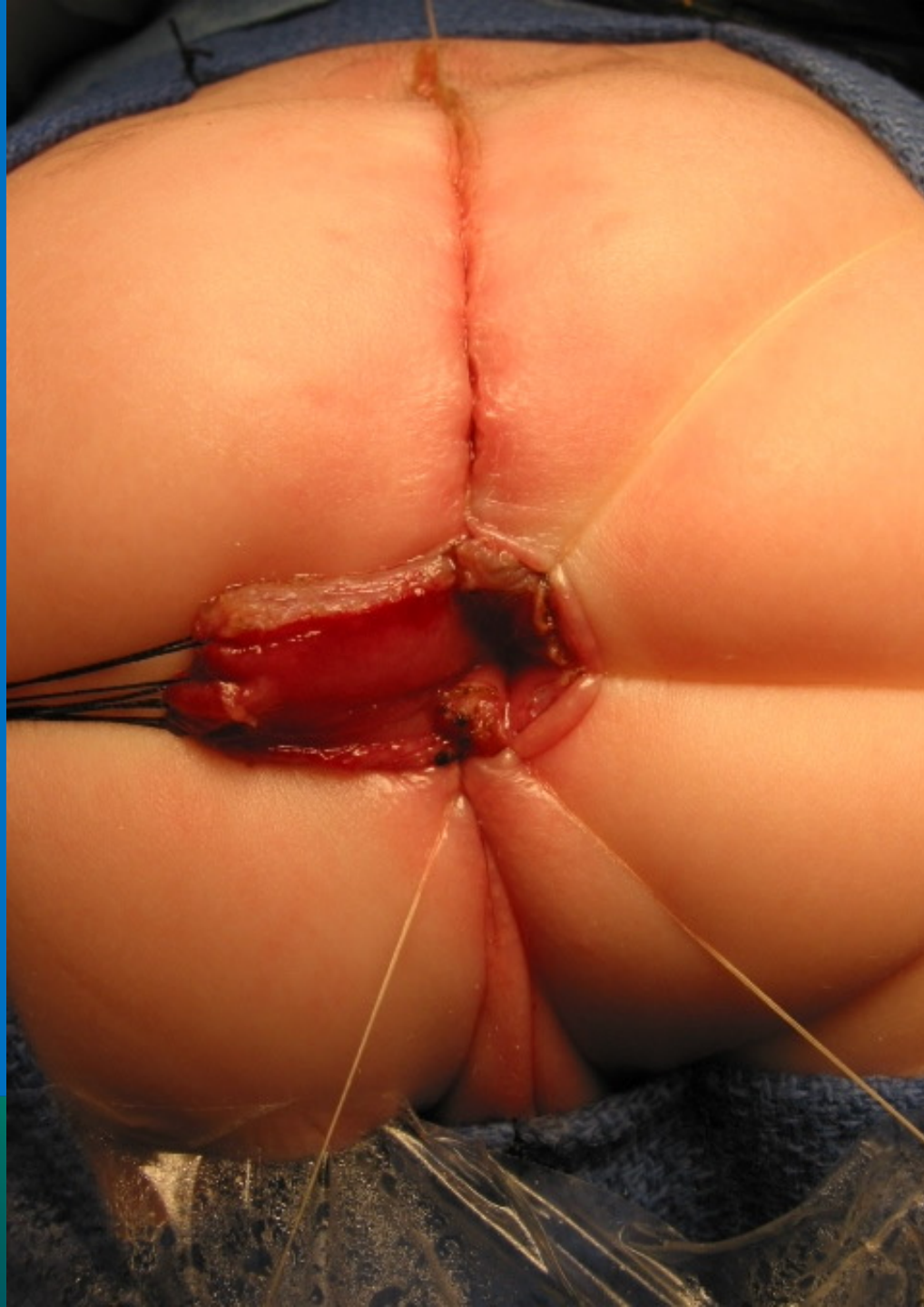


INTERNATIONAL CENTER FOR  
**COLORECTAL AND  
GENITAL CARE**

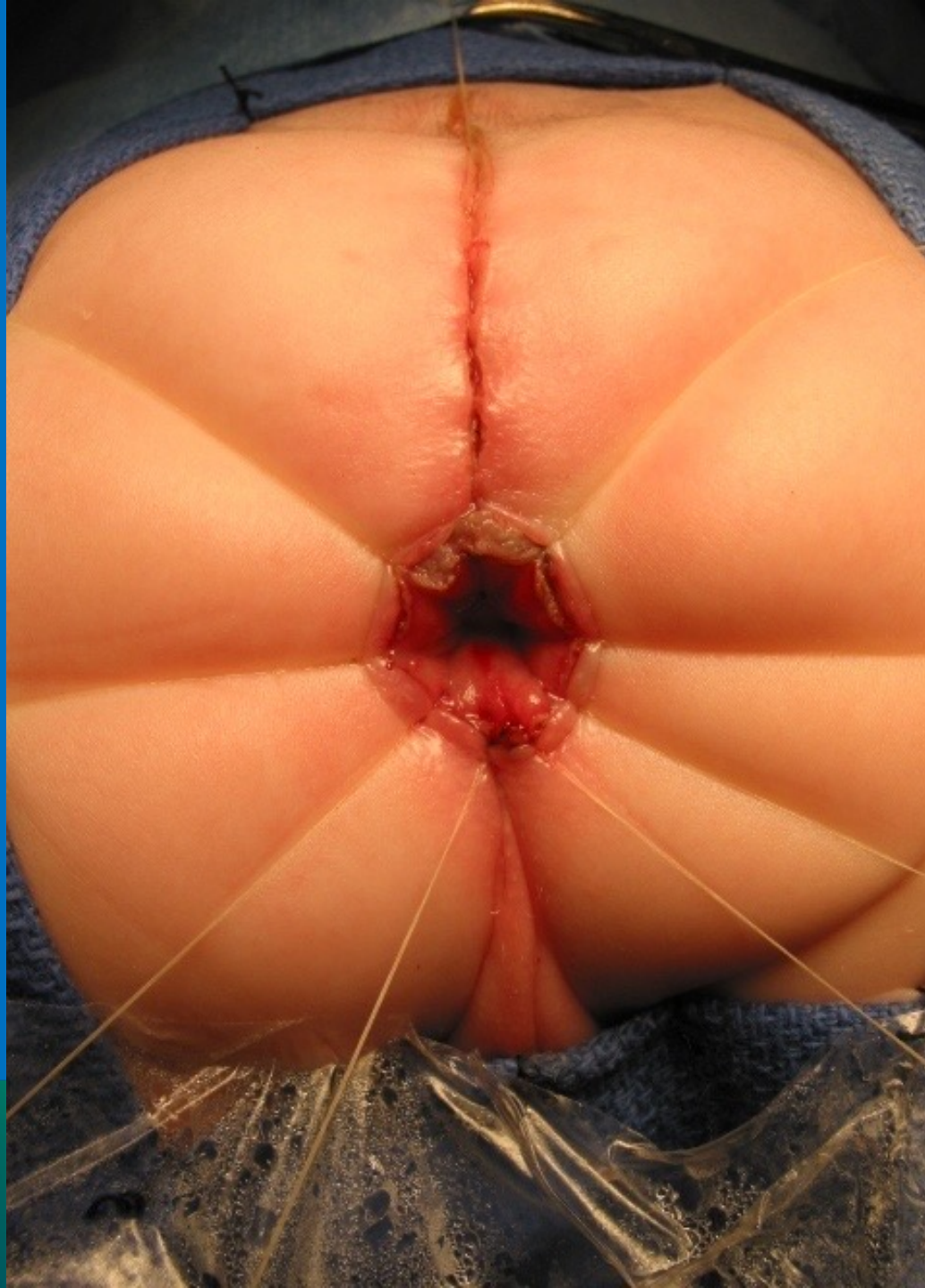




NATIONAL CENTER FOR  
**RECTAL AND  
ANAL CARE**

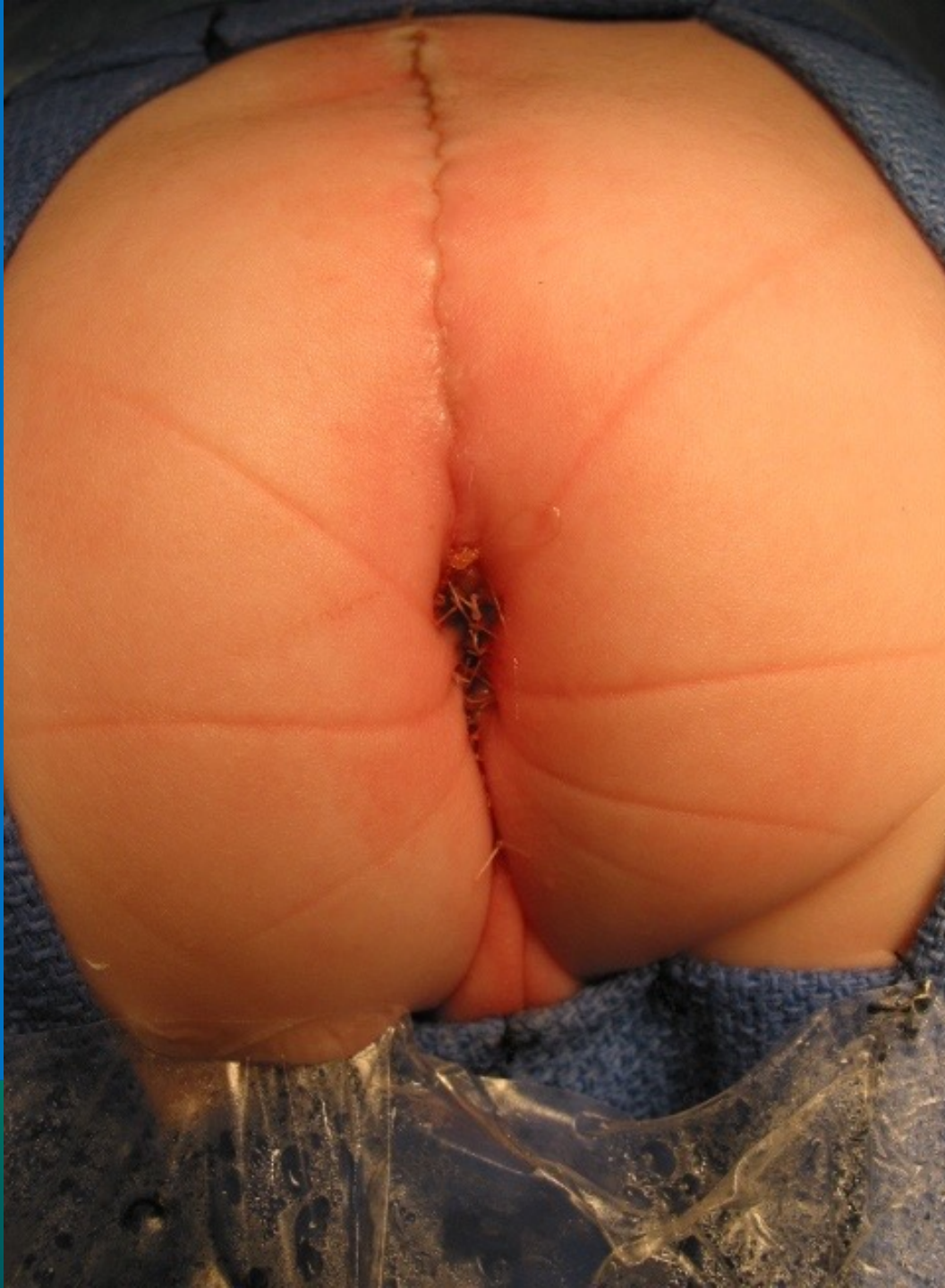

NATIONAL CENTER FOR  
**COLORECTAL AND  
GENITAL CARE**



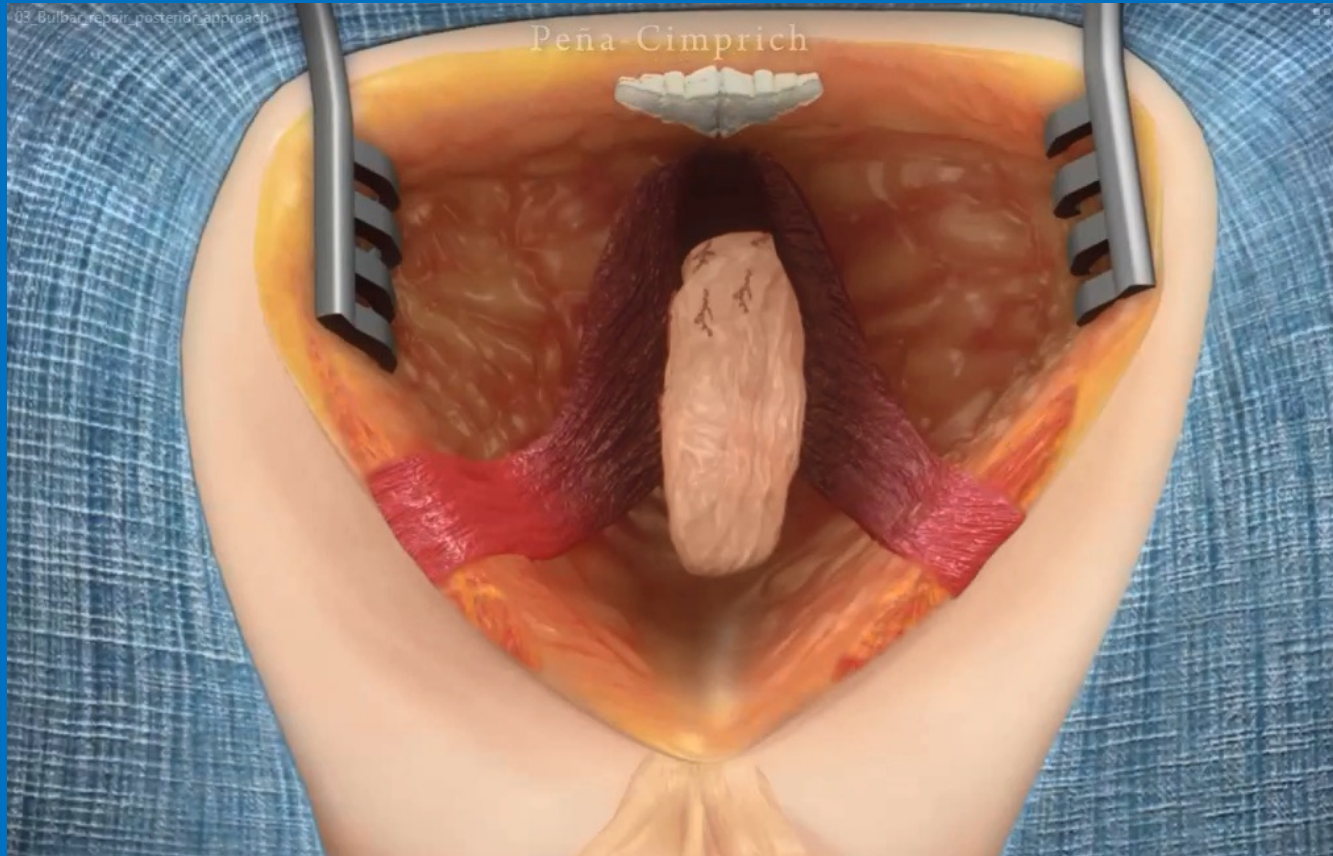
NATIONAL CENTER FOR  
**COLORECTAL AND  
GENITAL CARE**

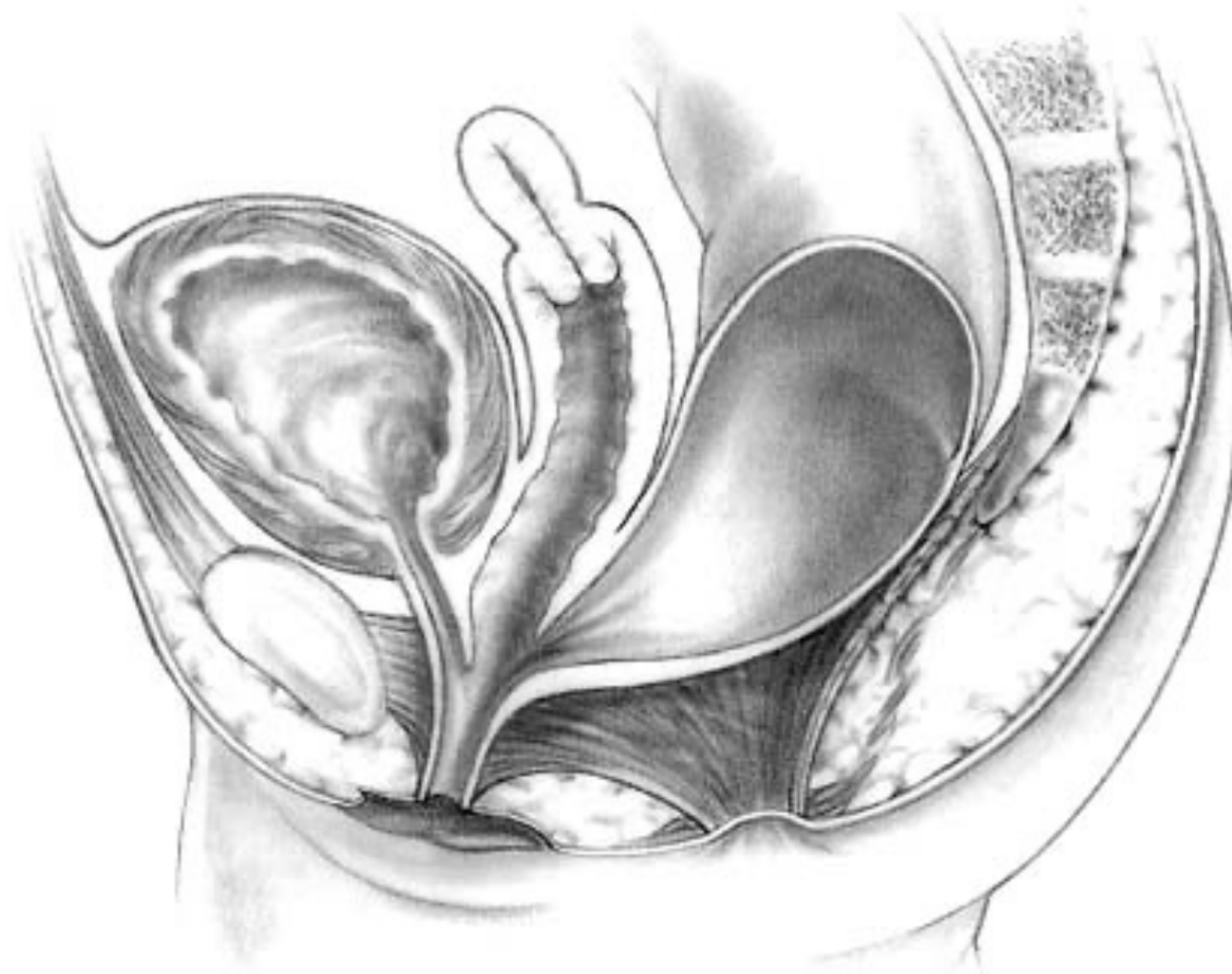




INTERNATIONAL CENTER FOR  
**RECTAL AND  
ANAL CARE**

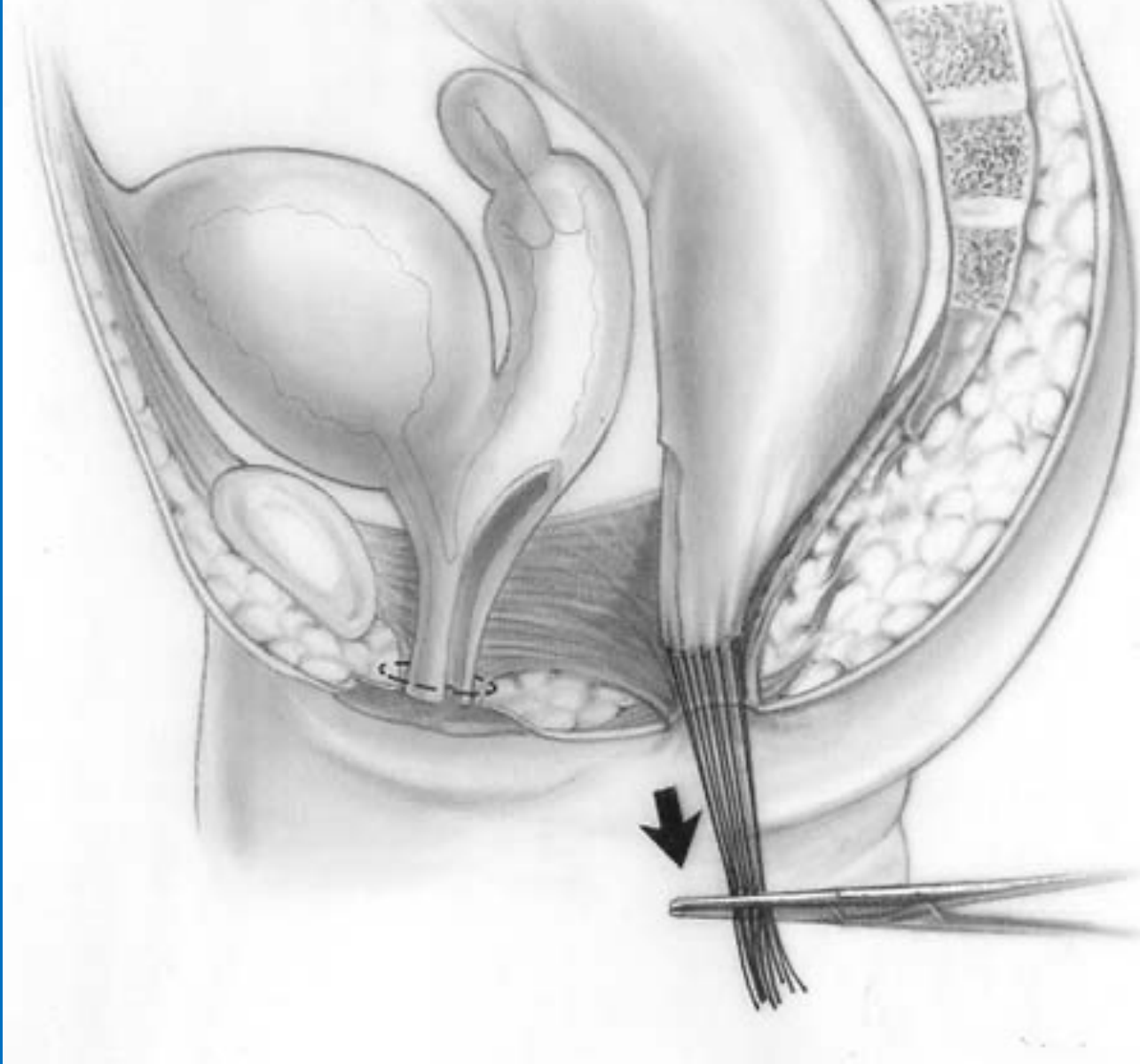
# Animation

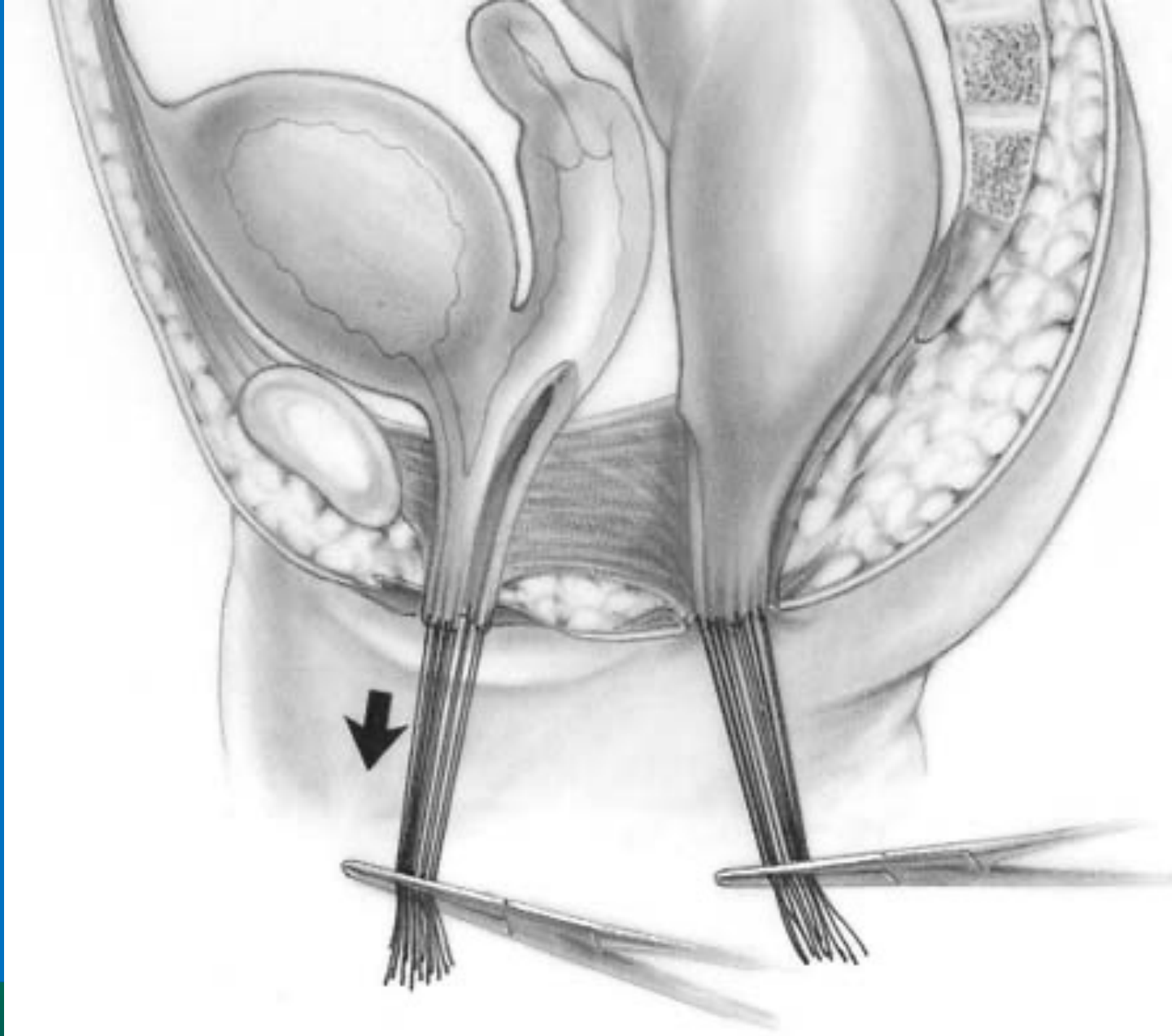




INTERNATIONAL CENTER FOR  
**COLORECTAL AND  
UROGENITAL CARE**

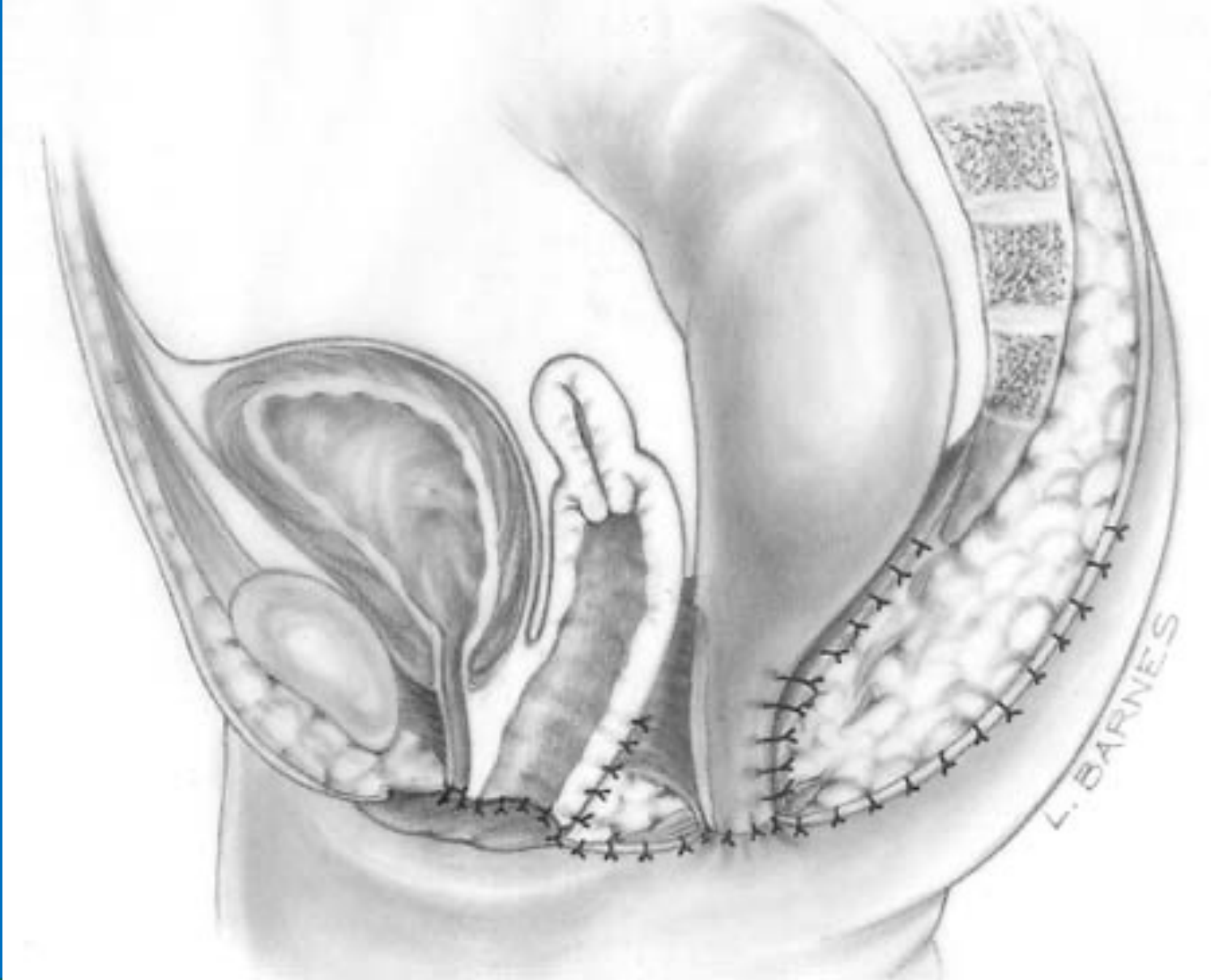

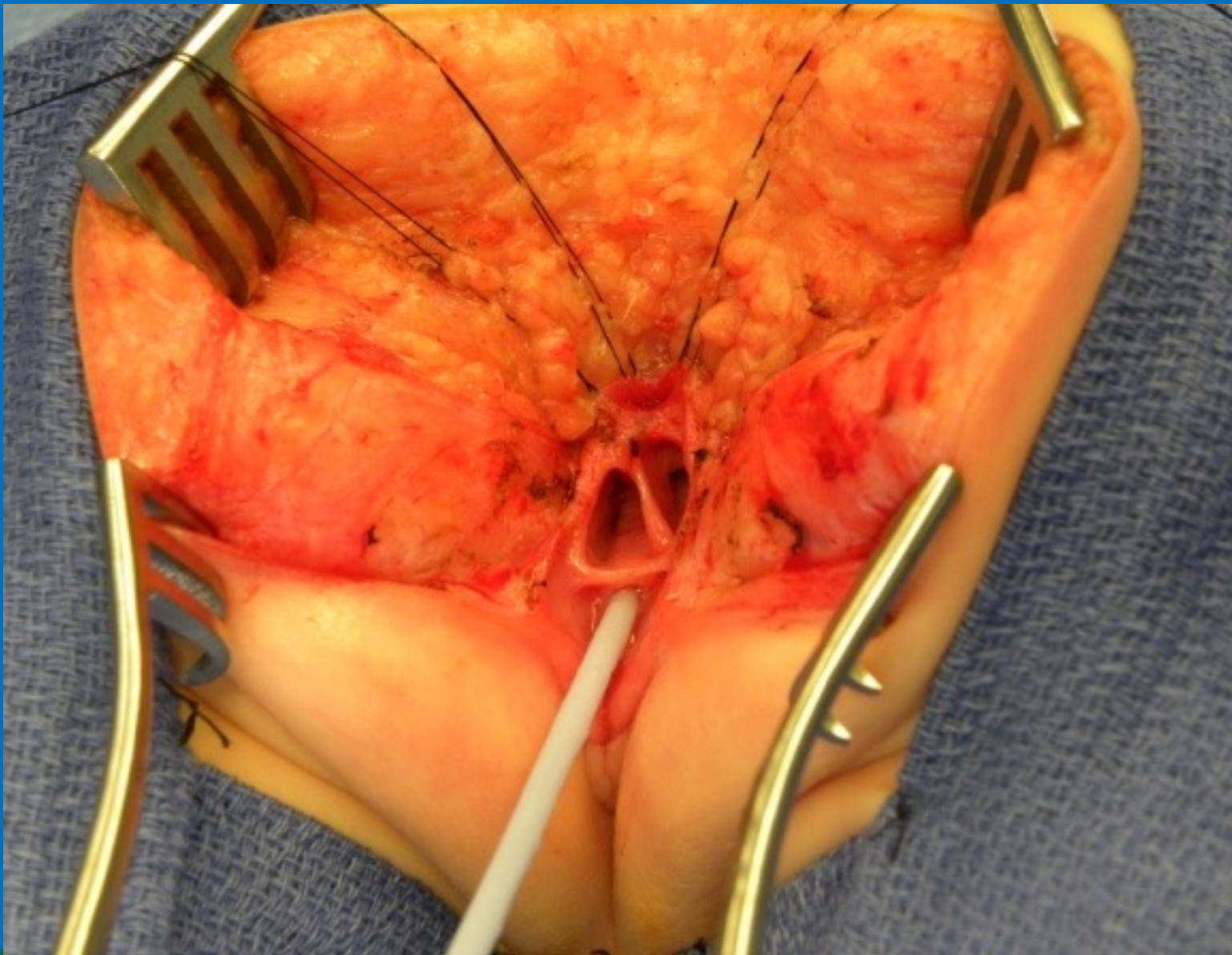




INTERNATIONAL CENTER FOR  
**COLORECTAL AND  
UROGENITAL CARE**

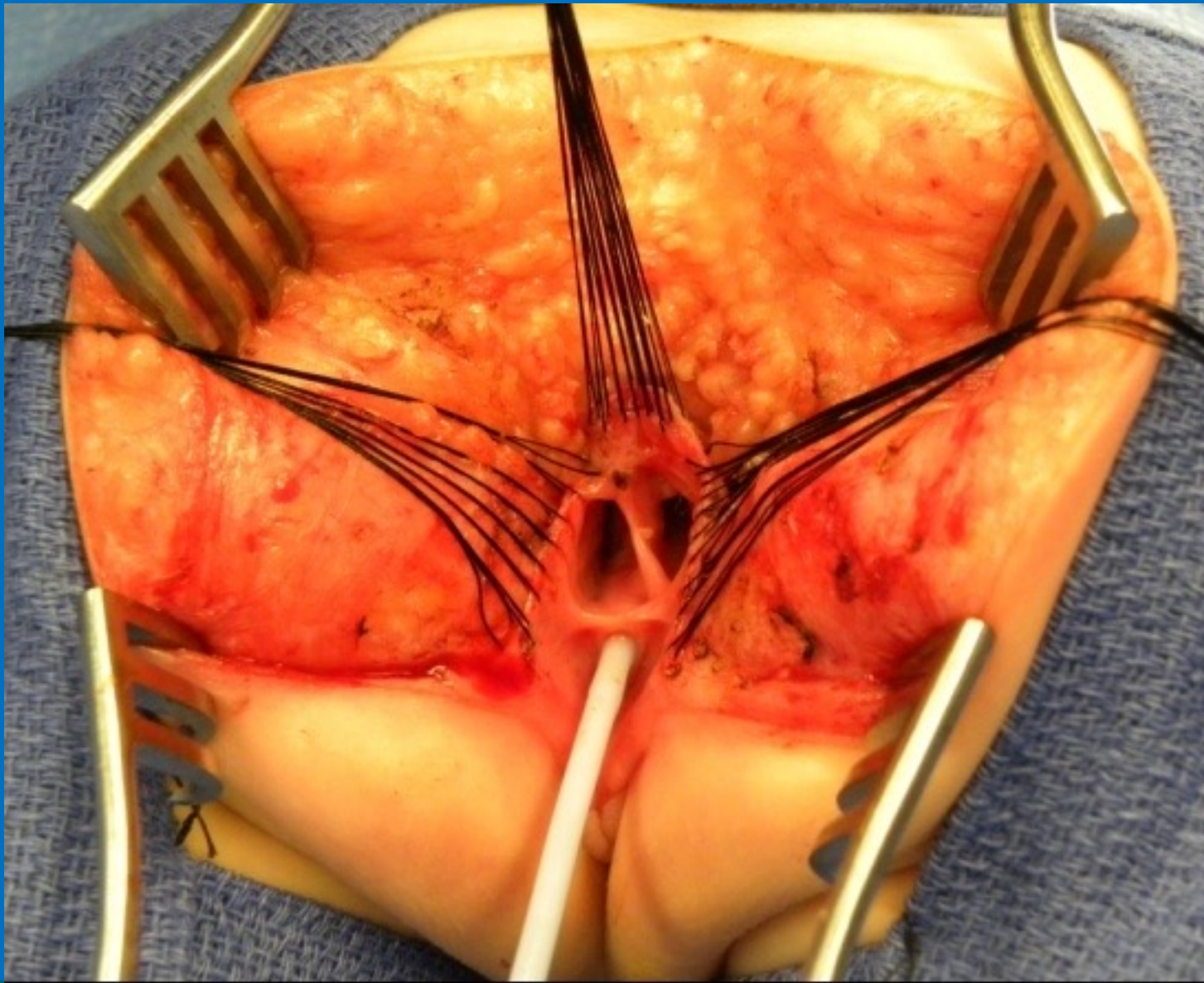




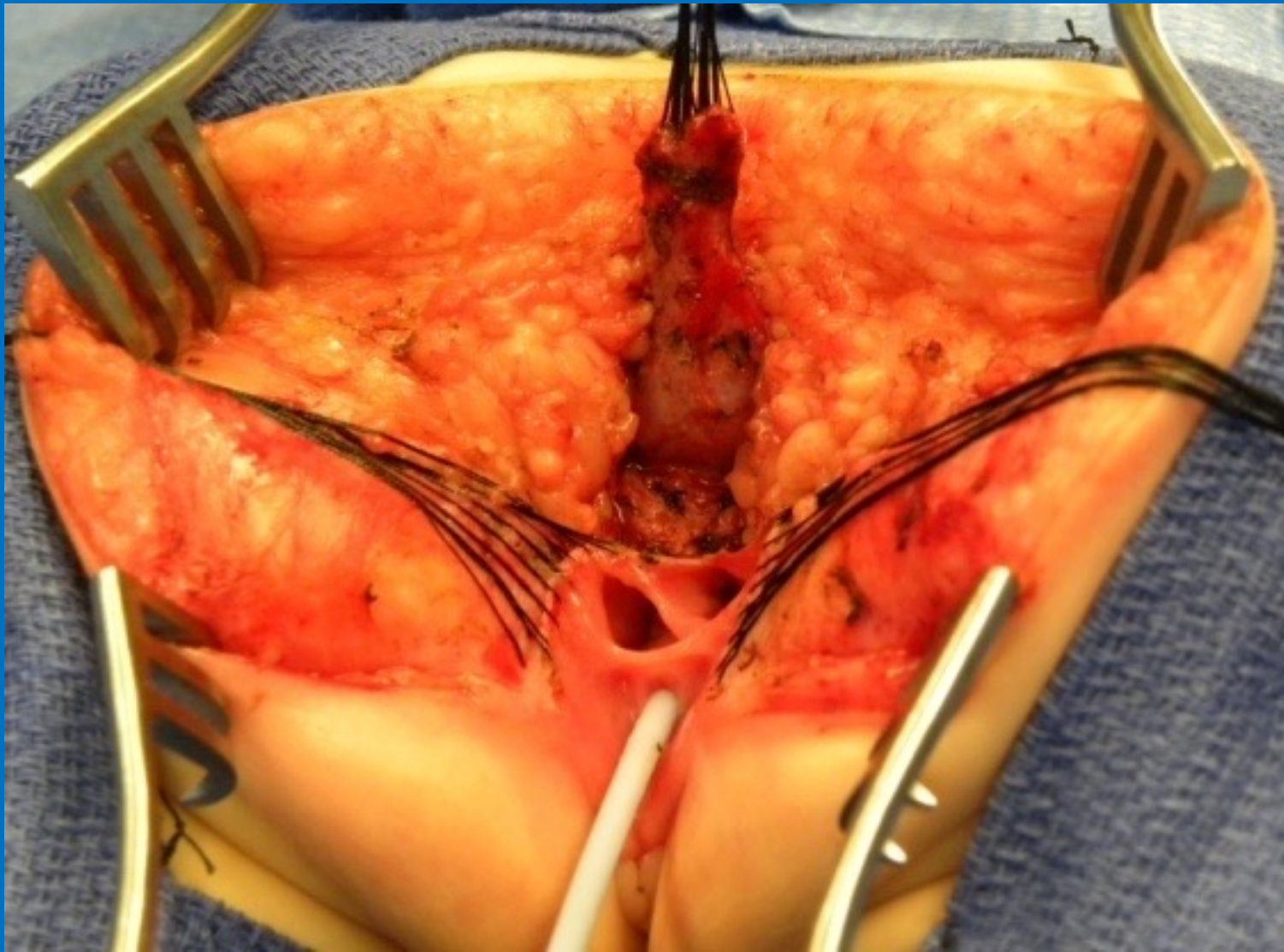


INTERNATIONAL CENTER FOR  
**COLORECTAL AND  
UROGENITAL CARE**

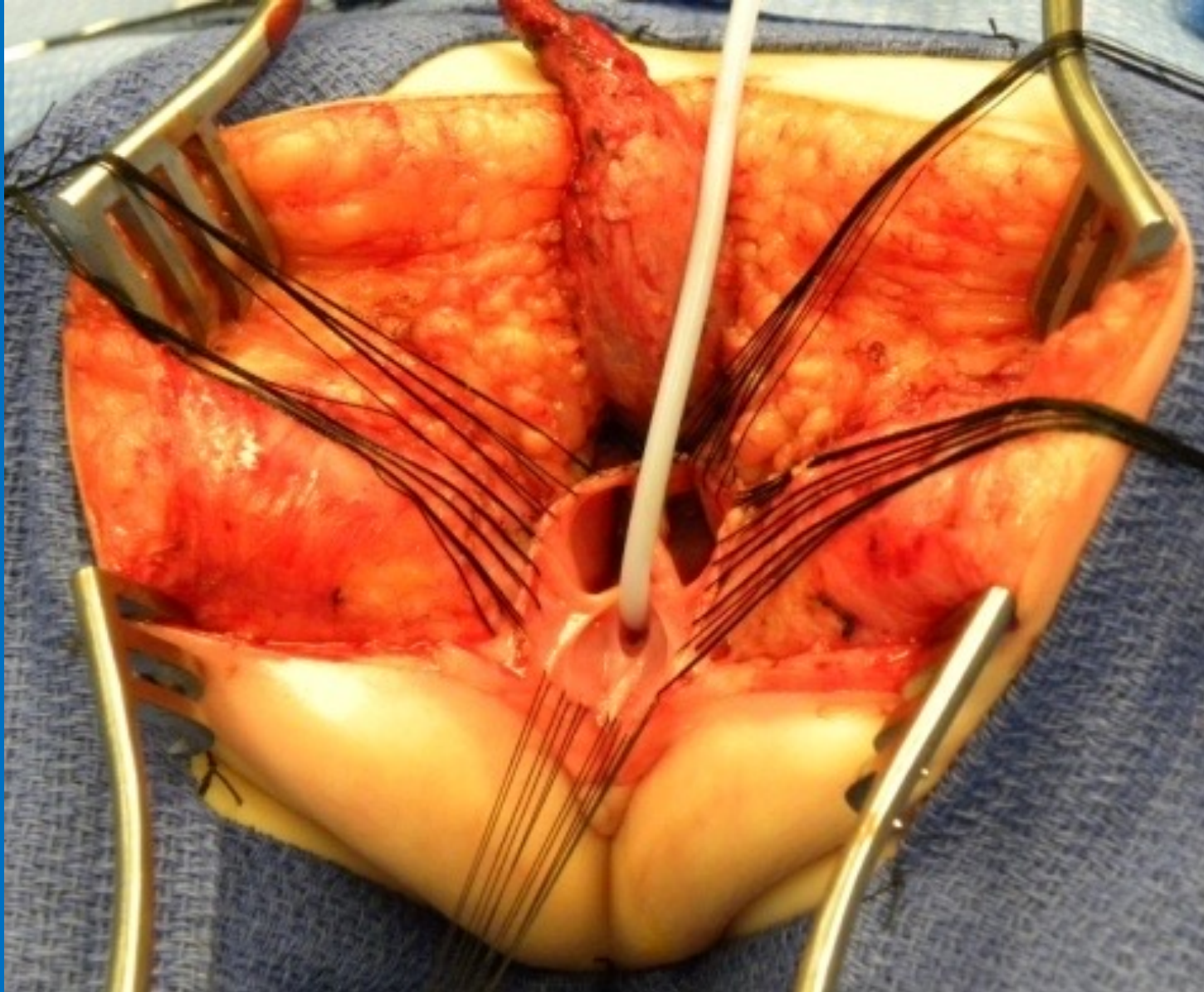




INTERNATIONAL CENTER FOR  
**COLORECTAL AND  
UROGENITAL CARE**

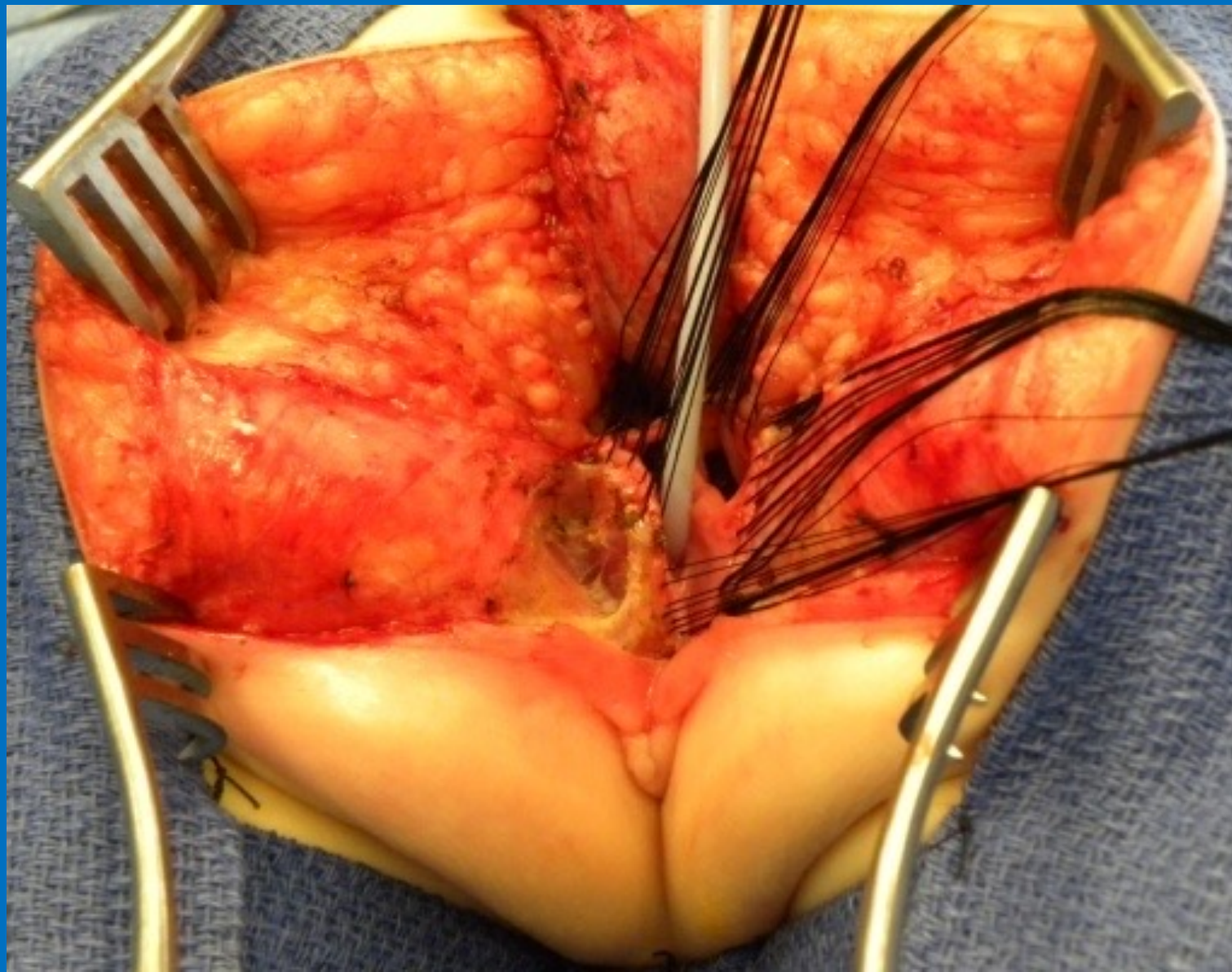




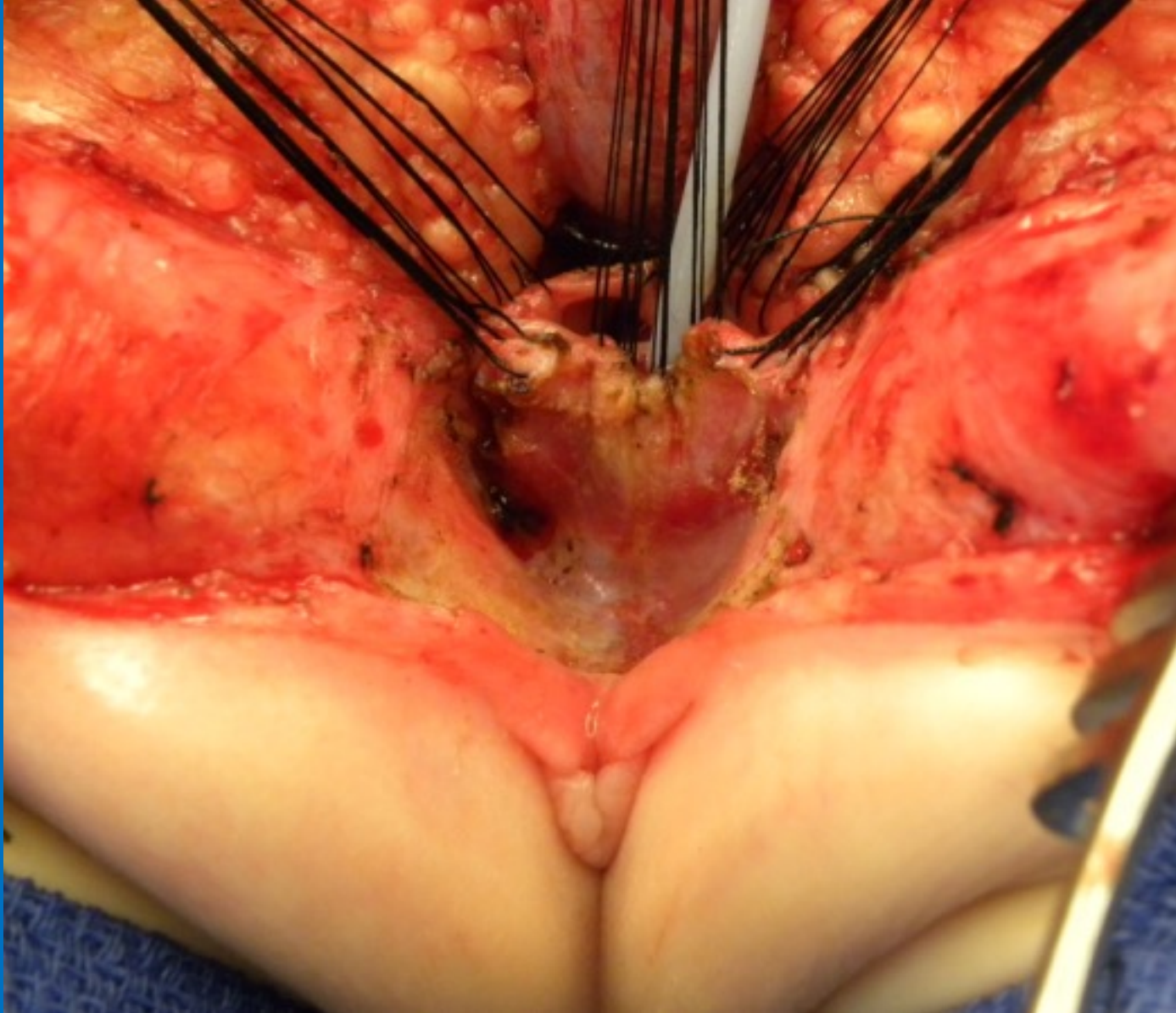


INTERNATIONAL CENTER FOR  
**COLORECTAL AND  
UROGENITAL CARE**



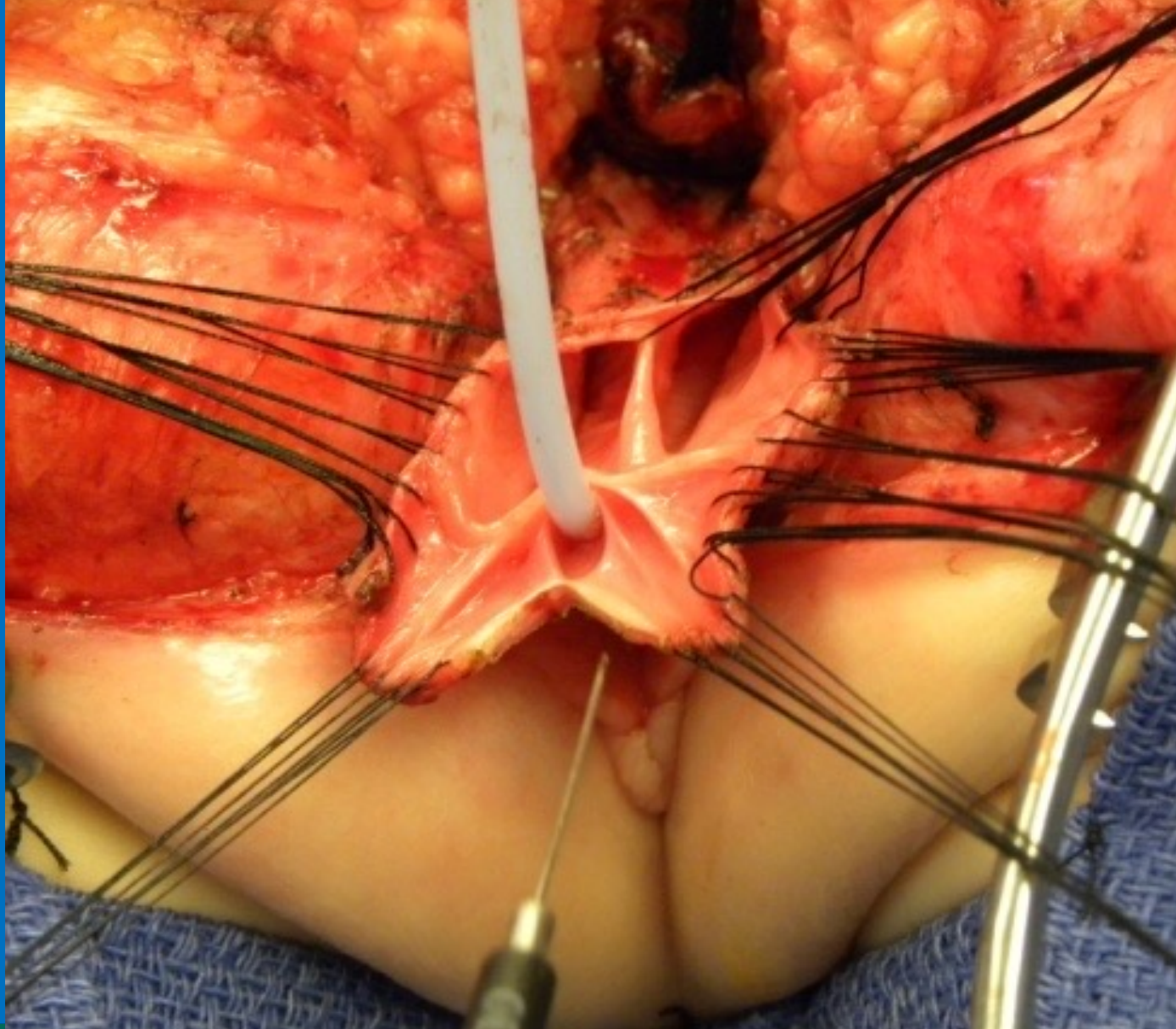


INTERNATIONAL CENTER FOR  
**COLORECTAL AND  
UROGENITAL CARE**



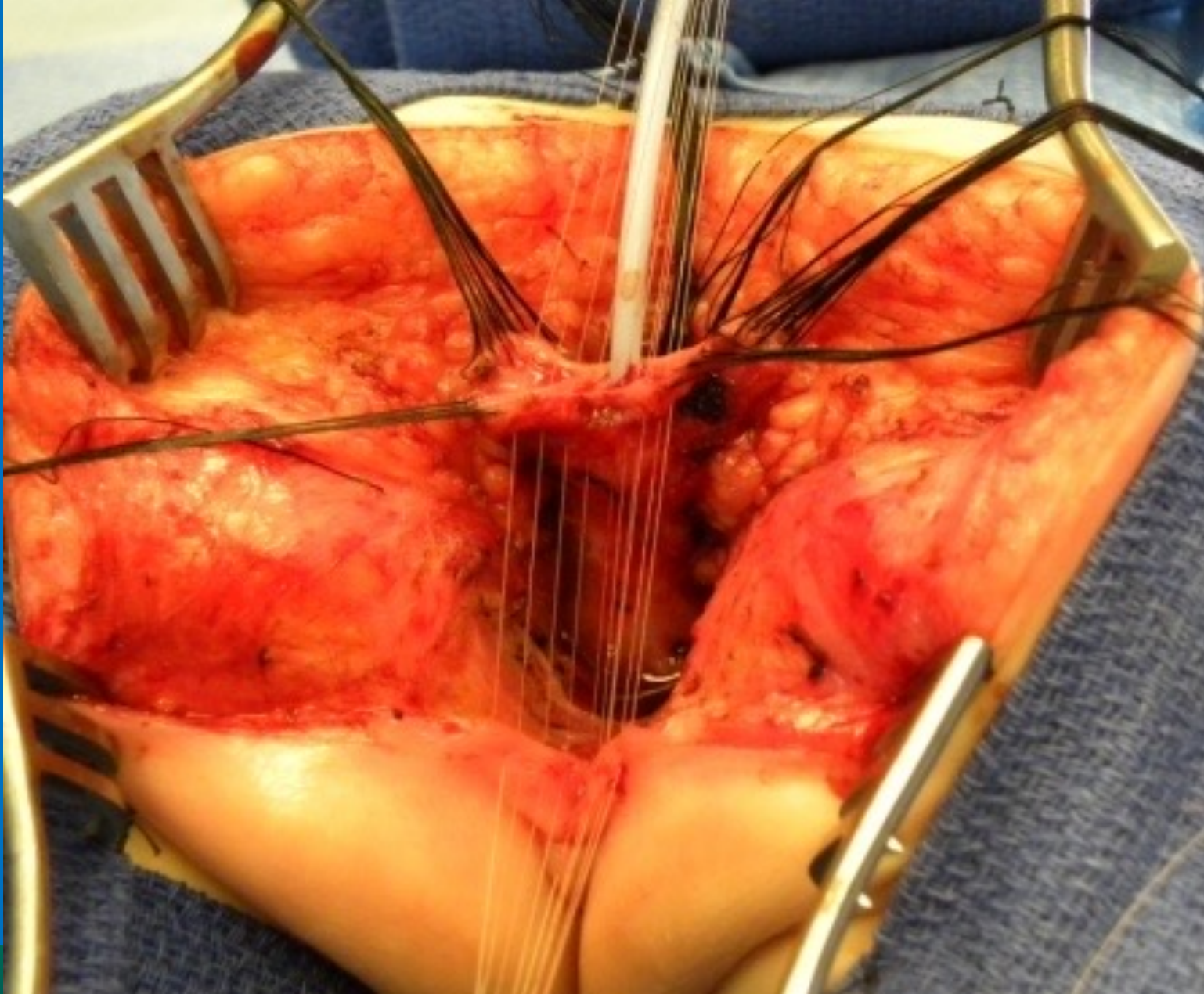
INTERNATIONAL CENTER FOR  
**COLORECTAL AND  
UROGENITAL CARE**



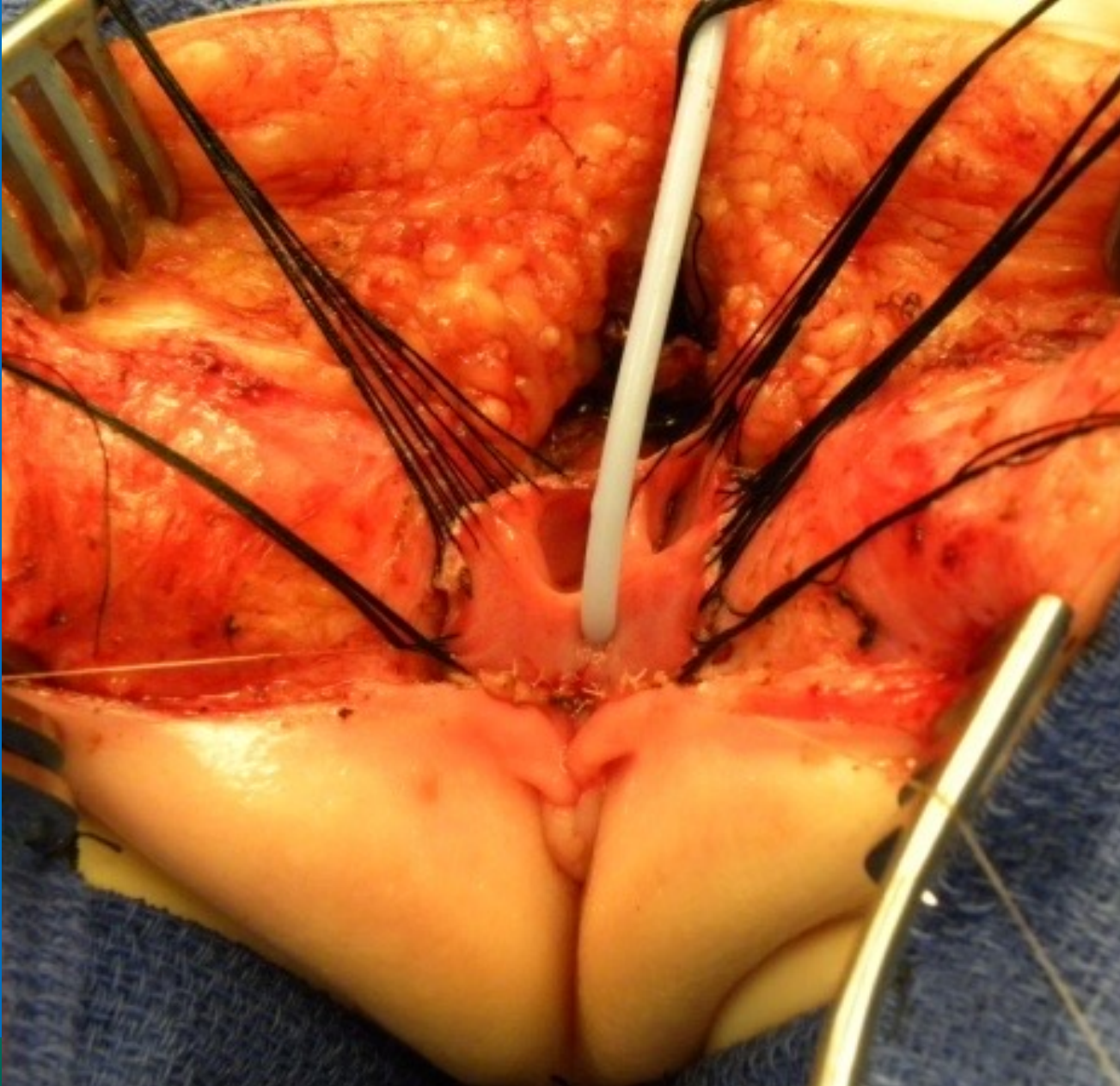


INTERNATIONAL CENTER FOR  
**COLORECTAL AND  
UROGENITAL CARE**



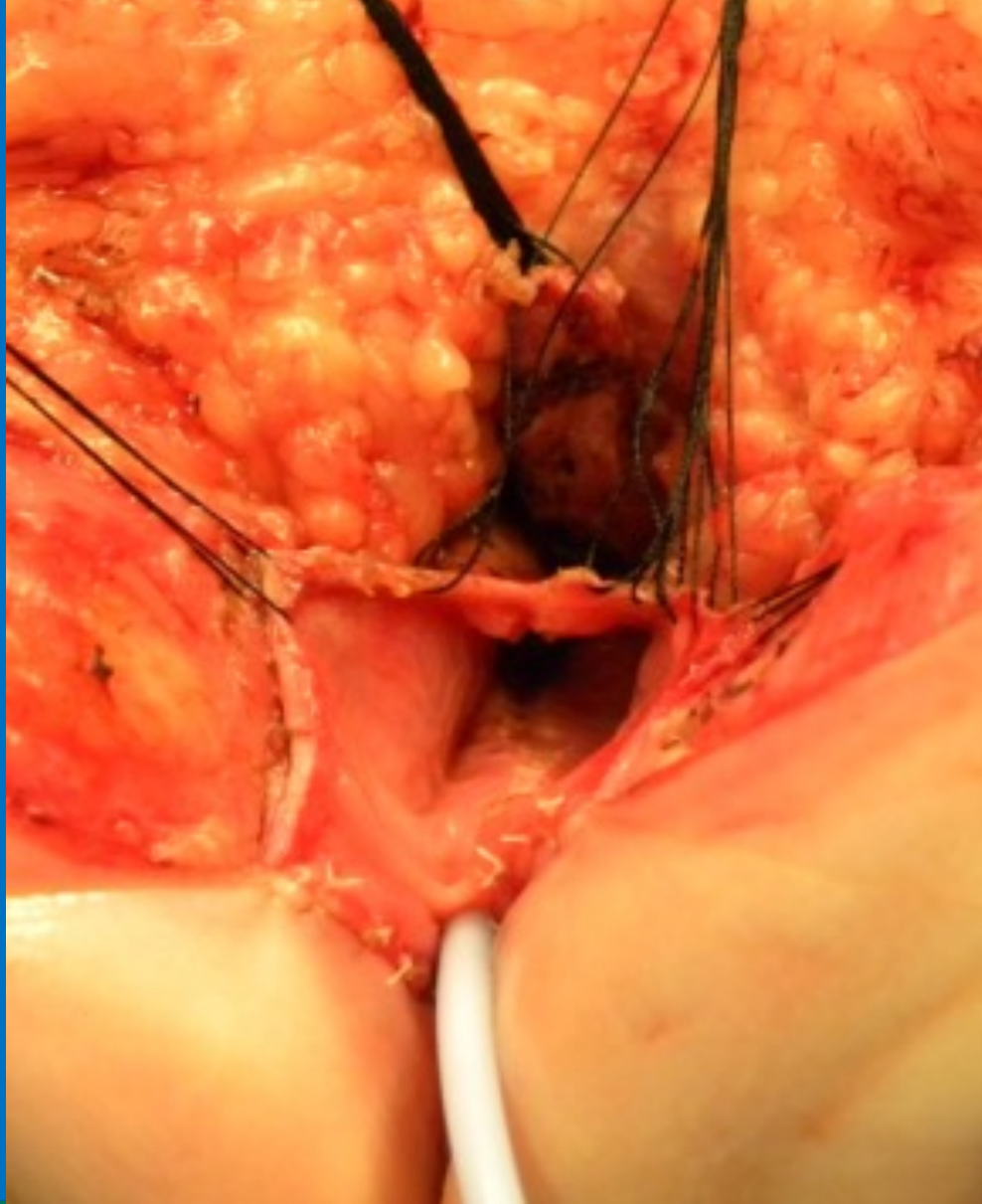


INTERNATIONAL CENTER FOR  
**COLORECTAL AND  
UROGENITAL CARE**



INTERNATIONAL CENTER FOR  
**COLORECTAL AND  
UROGENITAL CARE**





INTERNATIONAL CENTER FOR  
**COLORECTAL AND  
UROGENITAL CARE**



# Animation



## Total Urogenital Mobilization

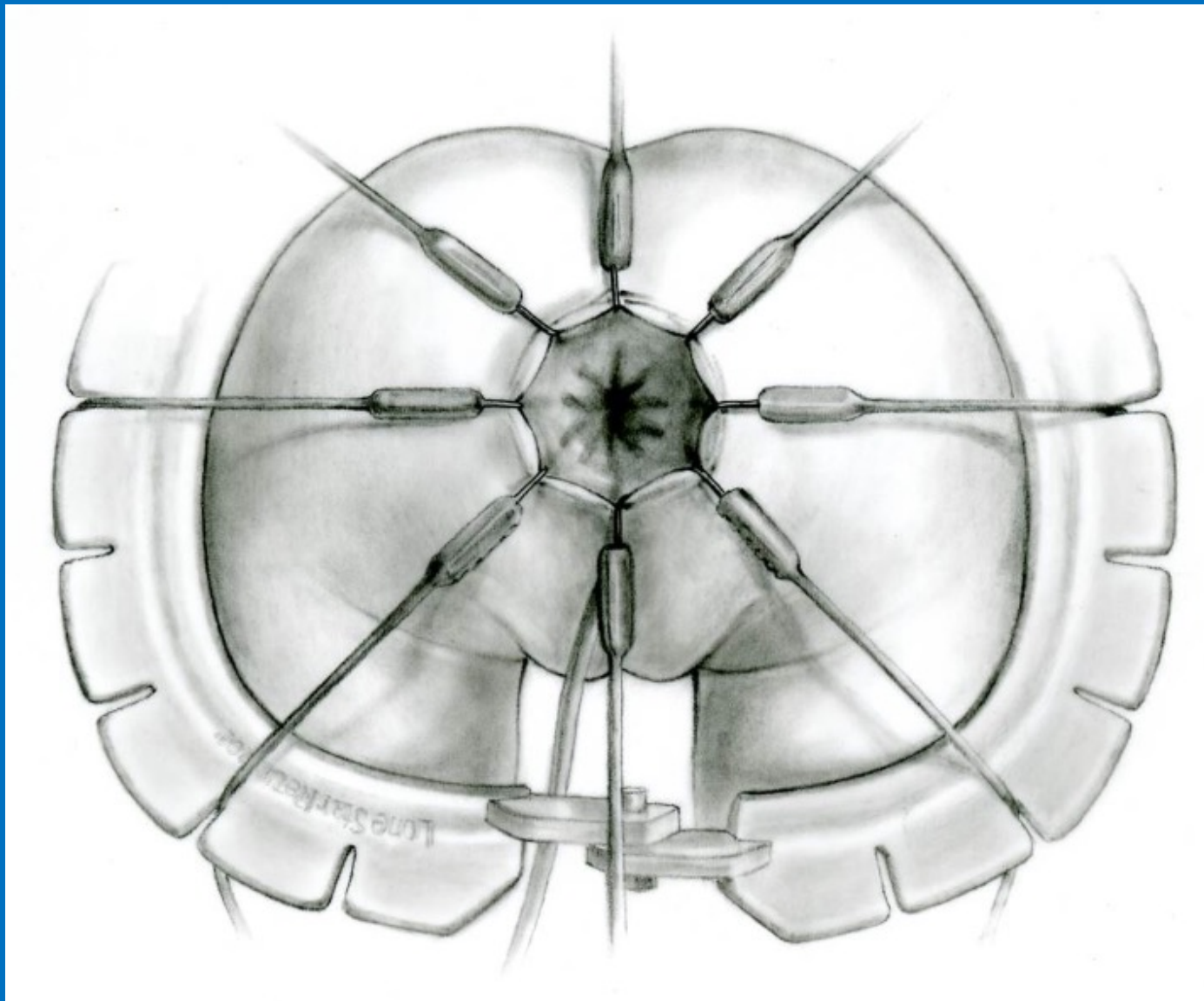


Children's Hospital Colorado  
International Center for  
Colorectal and Urogenital Care

October 10<sup>th</sup>, 1996

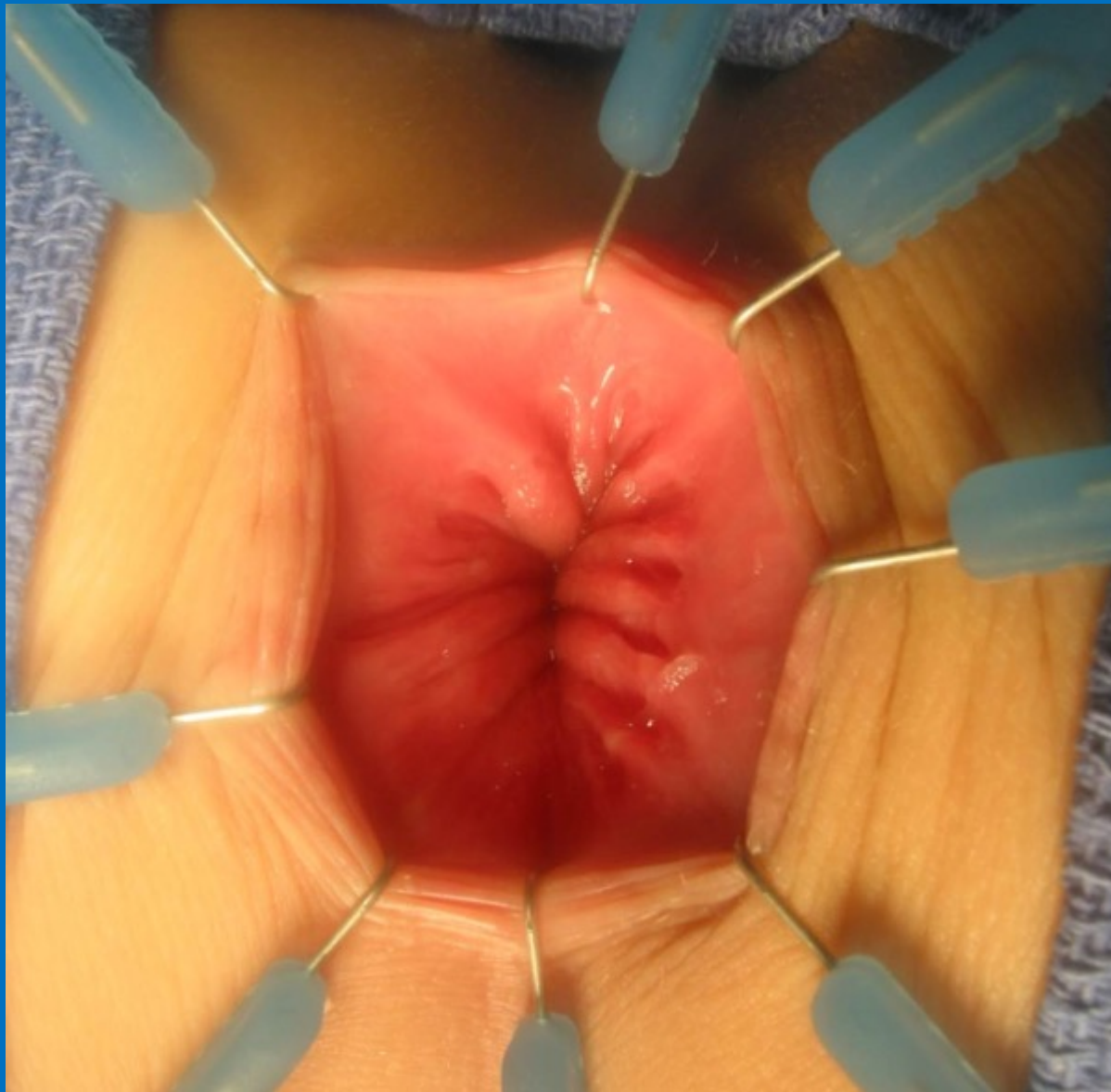


Luis de La Torre, Mexico City  
First transanal approach for  
Hirschsprung disease.

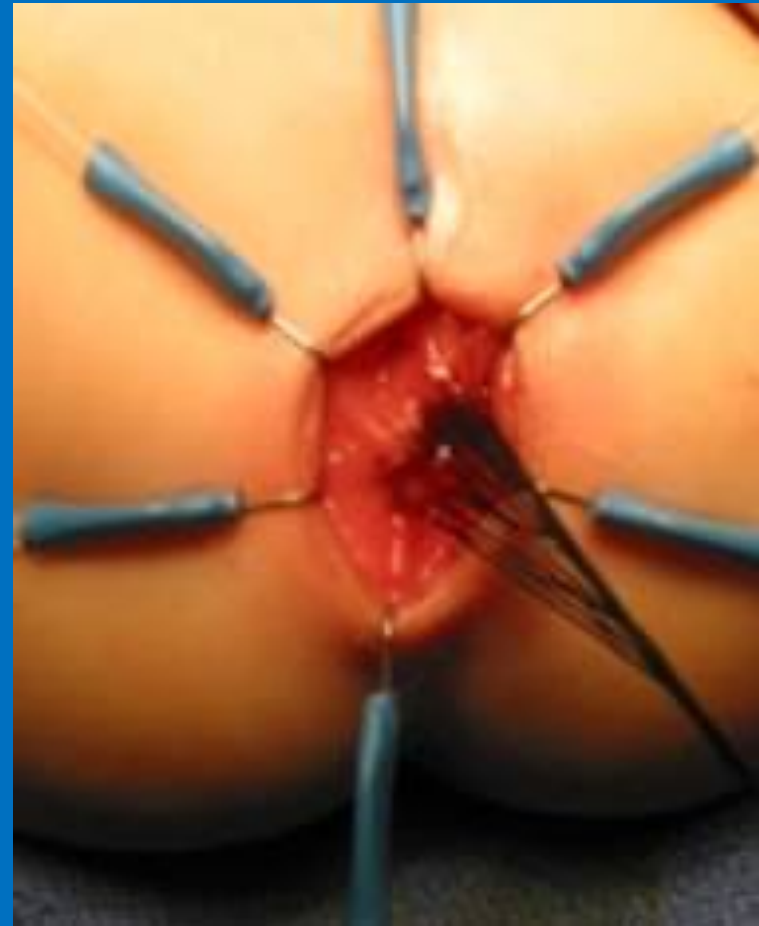
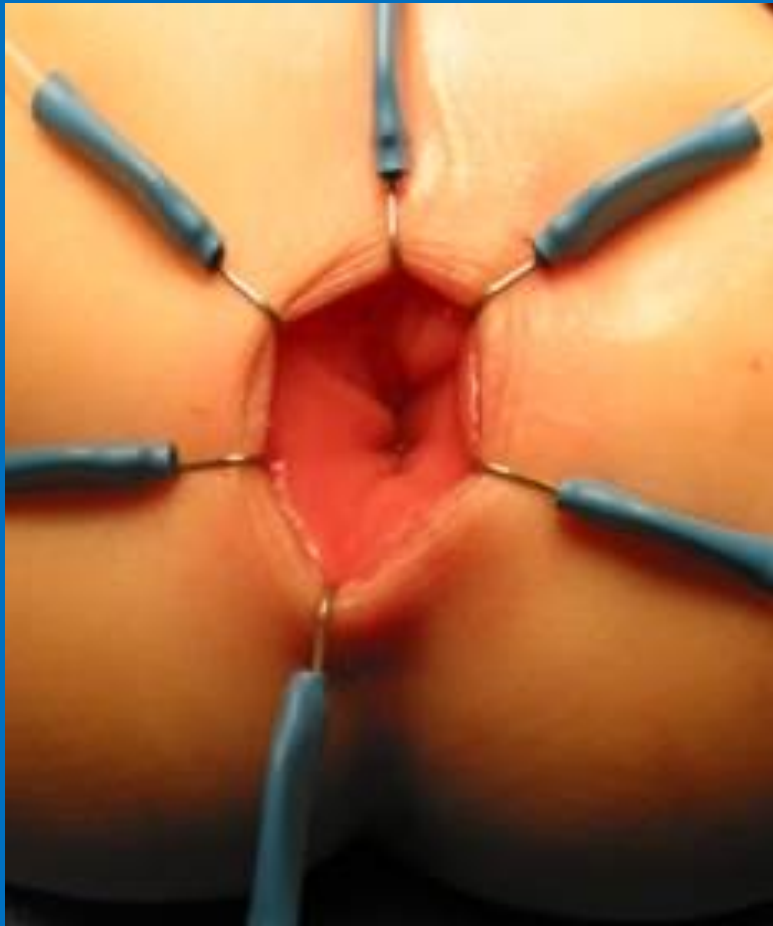
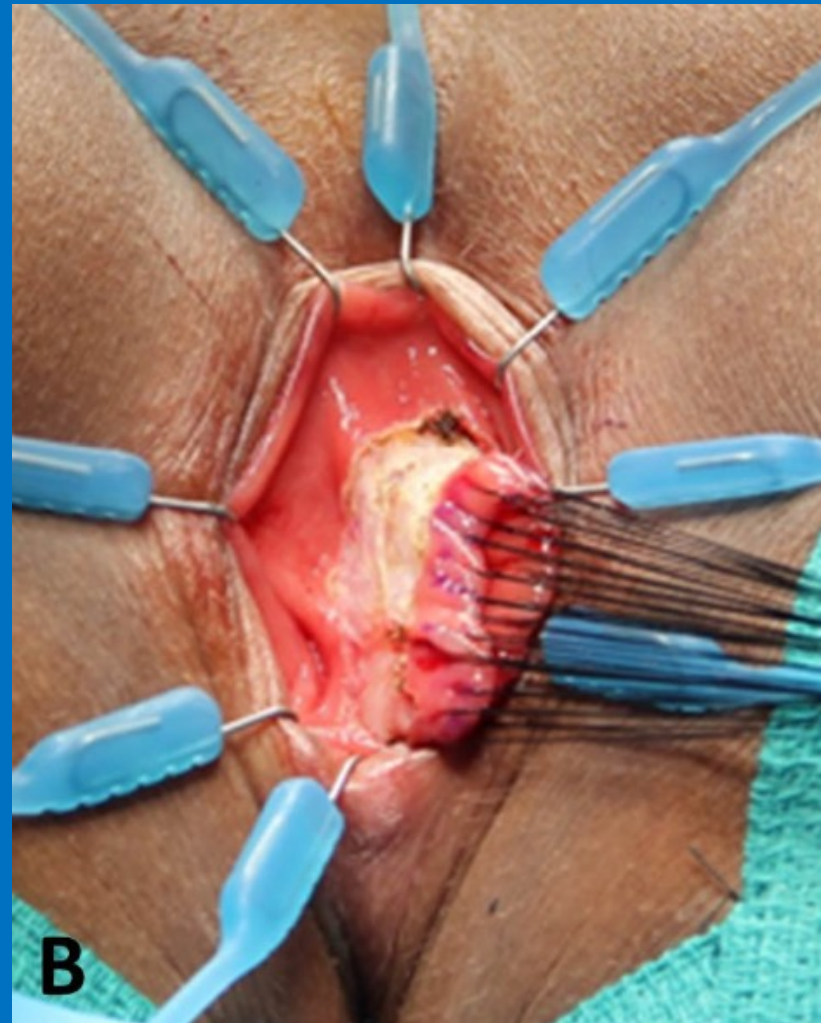
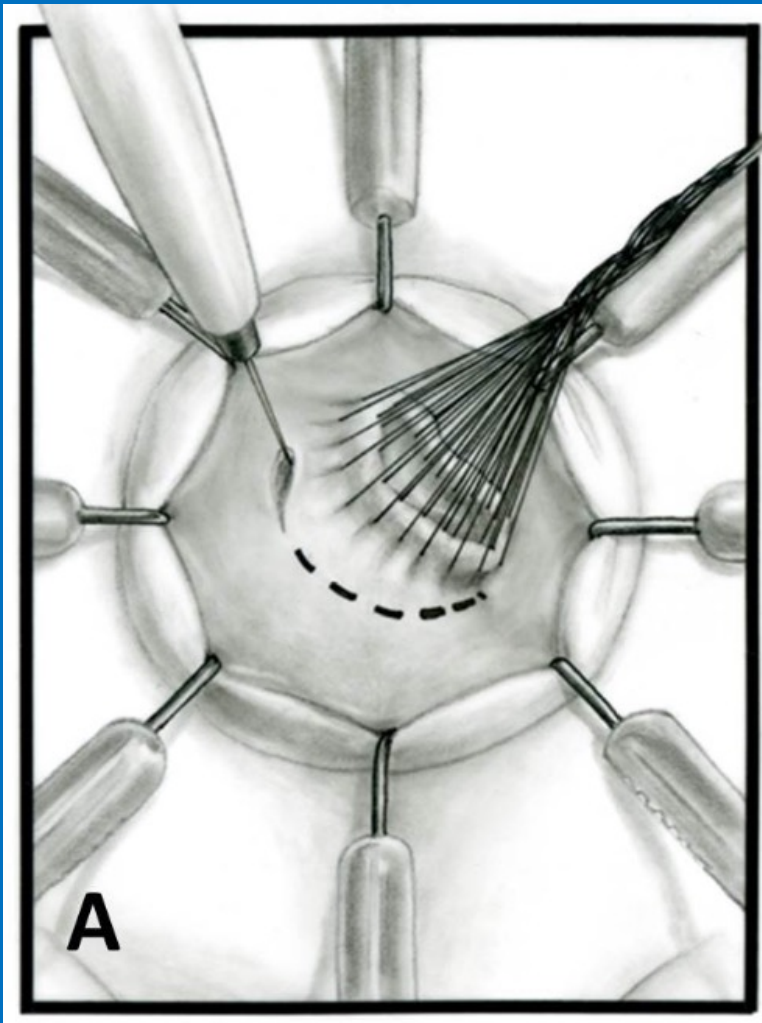
INTERNATIONAL CENTER FOR  
**COLORECTAL AND  
UROGENITAL CARE**



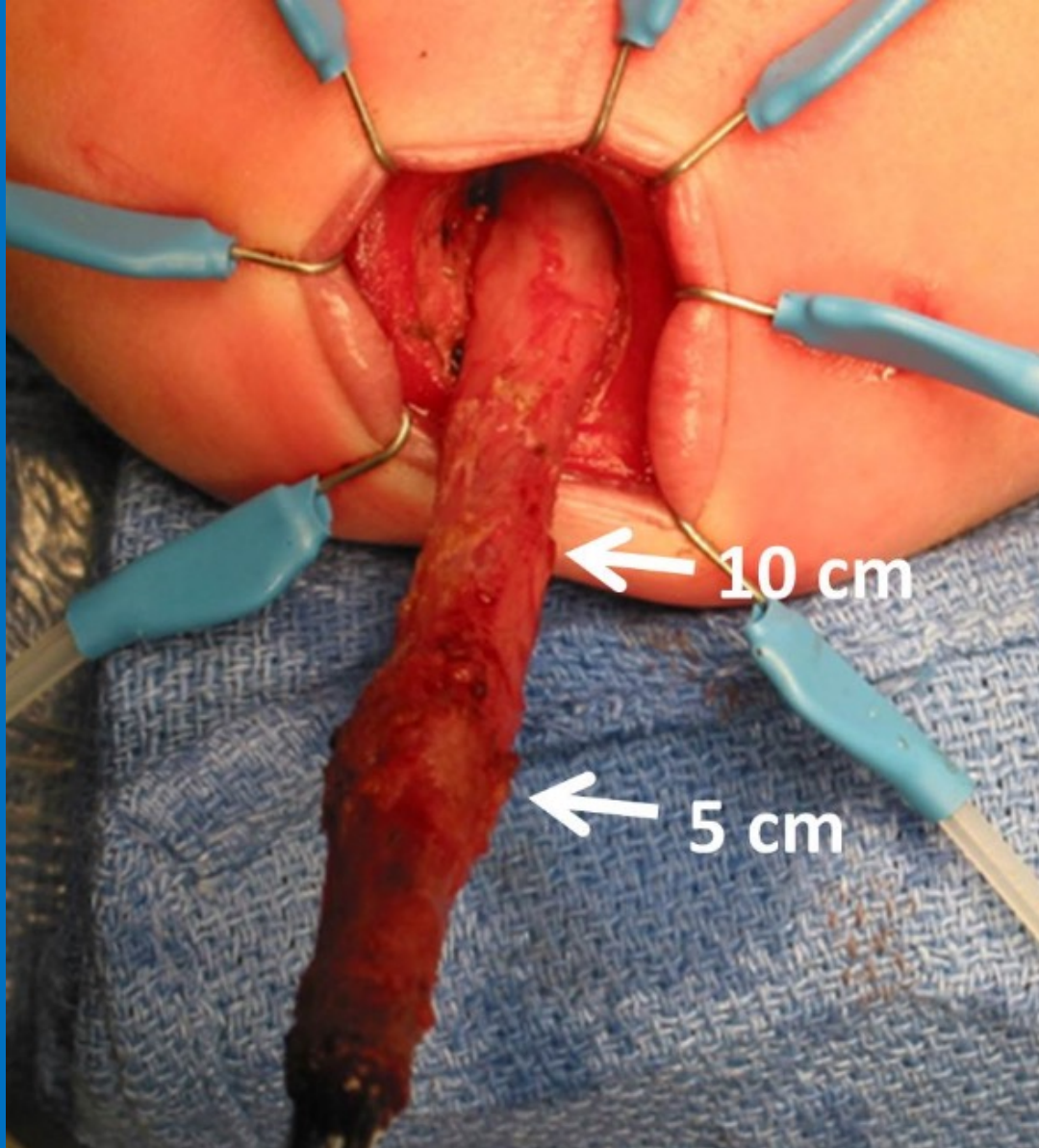


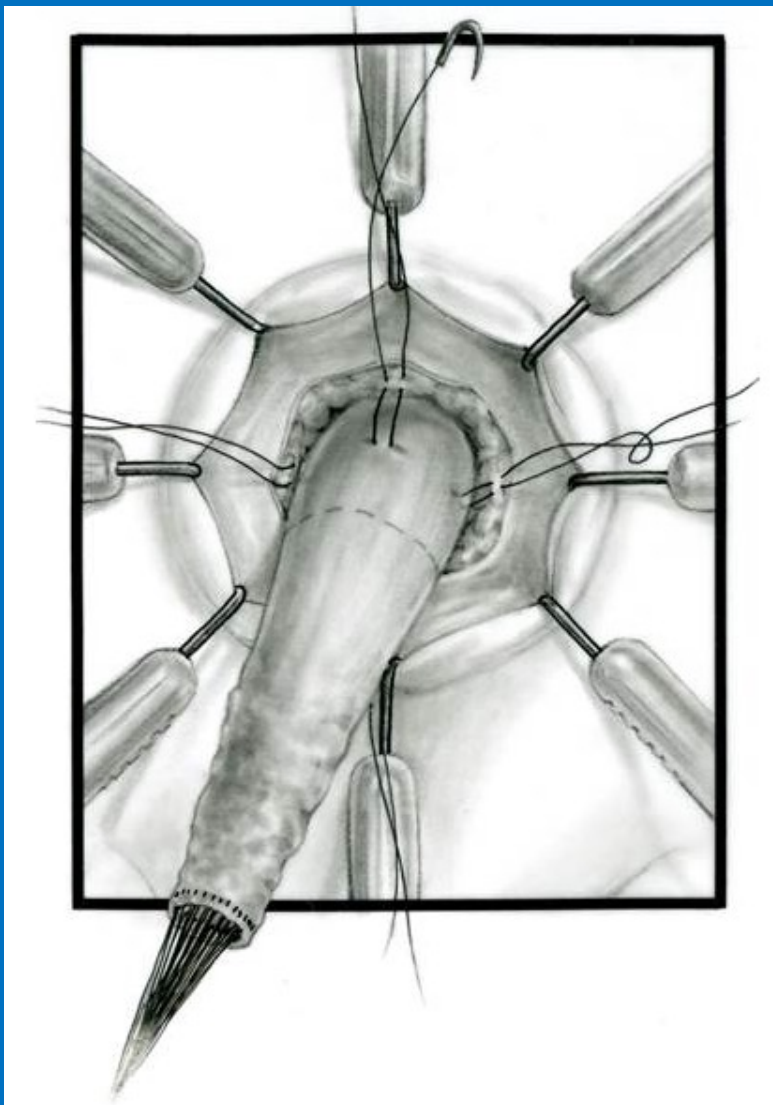
INTERNATIONAL CENTER FOR  
**COLORECTAL AND  
UROGENITAL CARE**

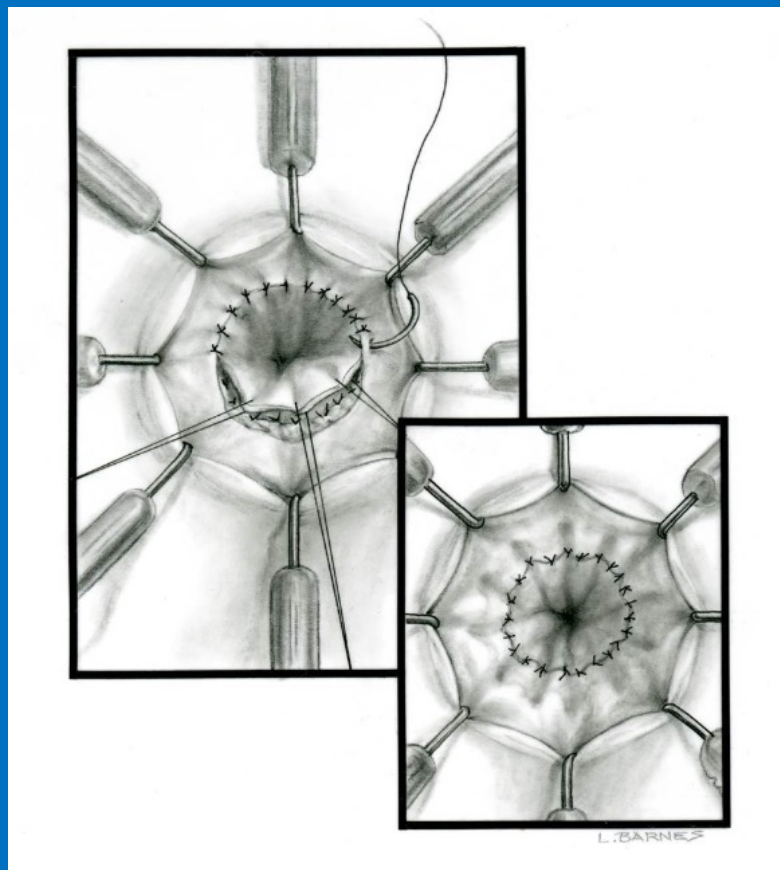
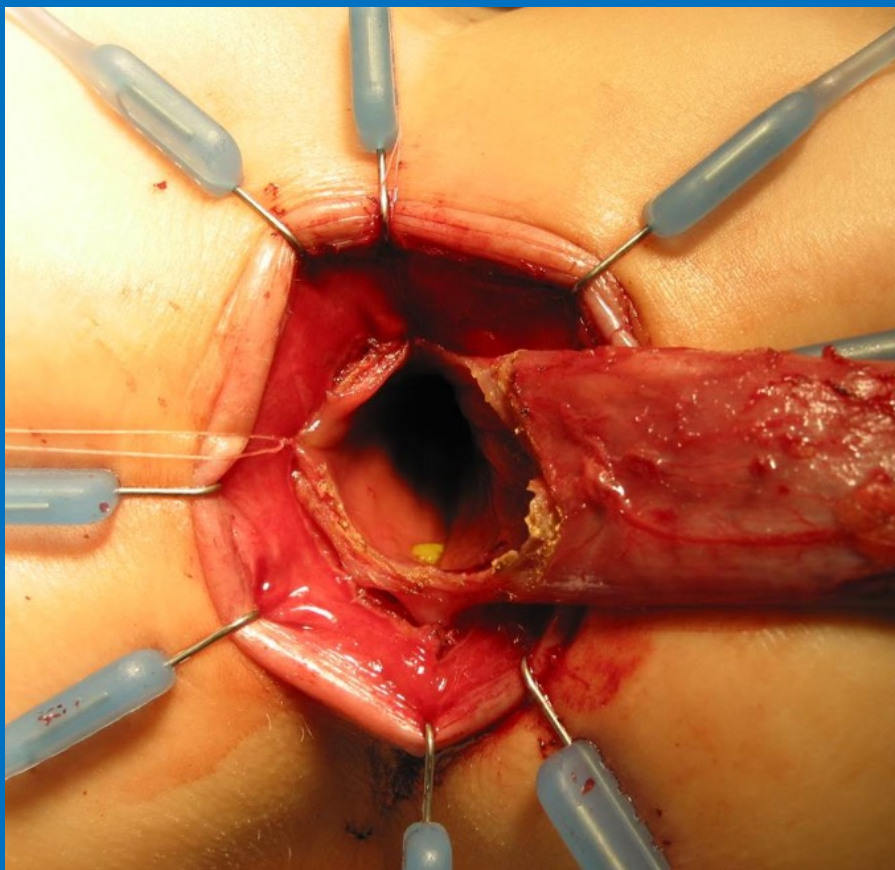






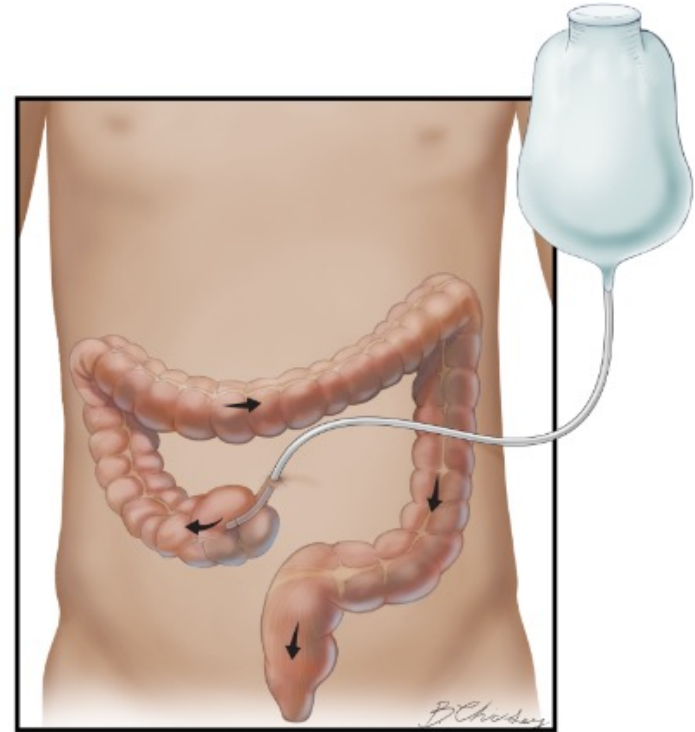
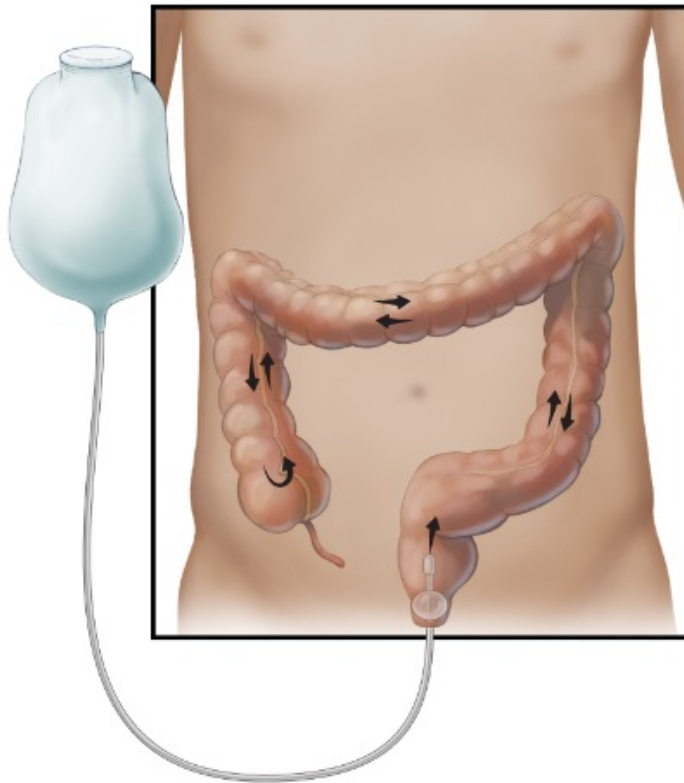








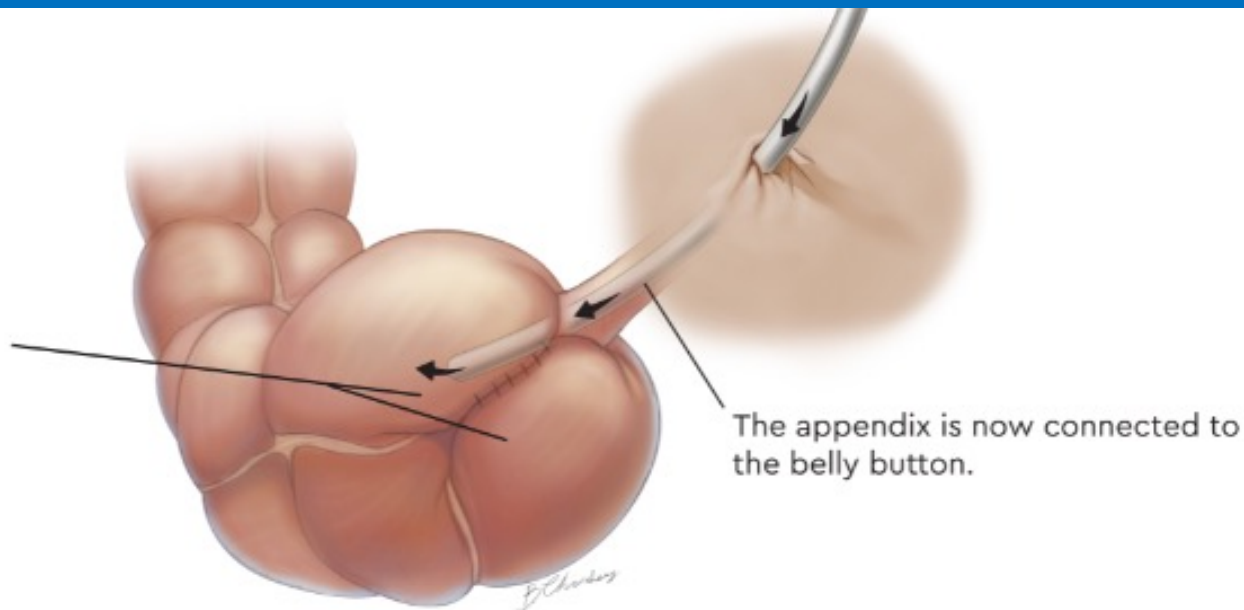
# Malone



Illustrations Copyright 2017 Regents of the University of Colorado.  
All Rights Reserved. Illustrations created by Berrien Chidsey.



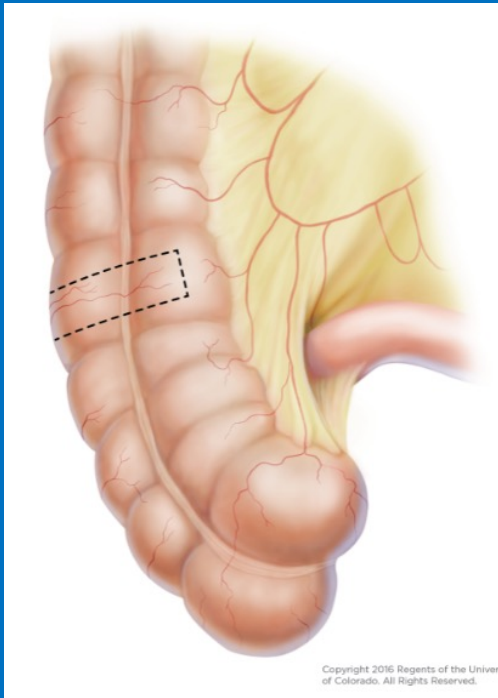
The cecum is sutured together around the appendix to create a valve that helps keep fluid and stool from leaking out the belly button.



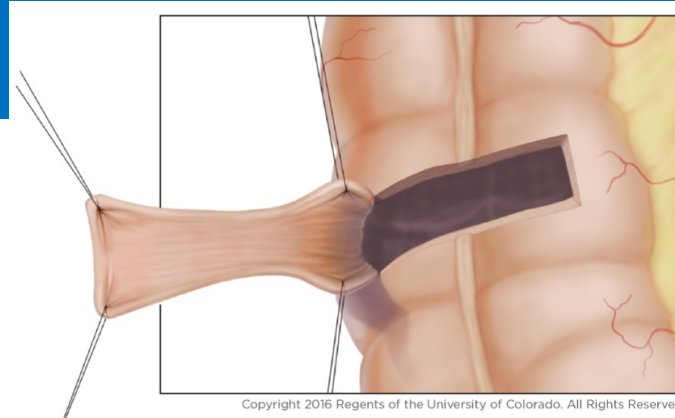
The appendix is now connected to the belly button.

Illustrations Copyright 2017 Regents of the University of Colorado. All Rights Reserved. Illustrations created by Berrien Chidsey.

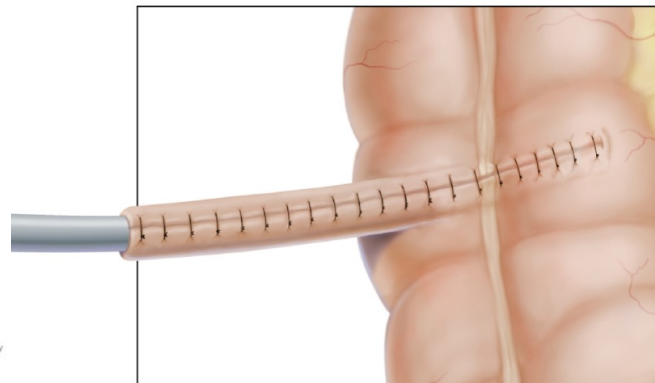# Neo-Malone



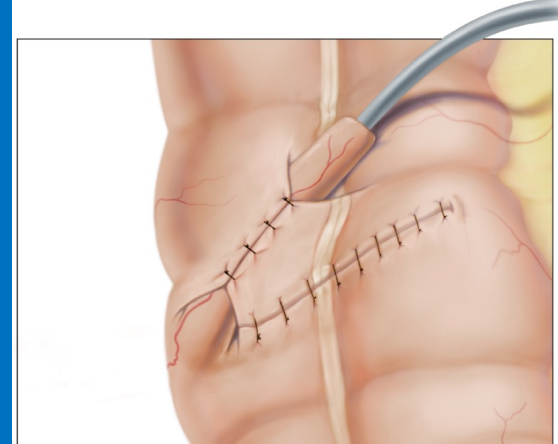
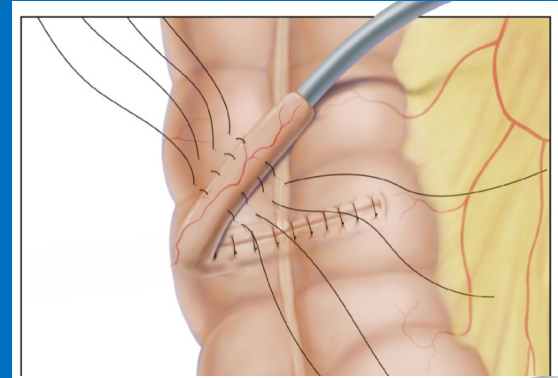
Copyright 2016 Regents of the University of Colorado. All Rights Reserved.



Copyright 2016 Regents of the University of Colorado. All Rights Reserved.



Copyright 2016 Regents of the University of Colorado. All Rights Reserved.



Copyright 2016 Regents of the University of Colorado. All Rights Reserved.



# Thank you!



[Andrea.Bischoff@cuanschutz.edu](mailto:Andrea.Bischoff@cuanschutz.edu)

[Andrea.Bischoff@childrenscolorado.org](mailto:Andrea.Bischoff@childrenscolorado.org)



Doctors Pena Bischoff



@DrsPenaBischoff



PENABISCHOFF